Review

Diagnosis, treatment and prognosis of lung abscess

Angeliki A. Loukeri, MD[1]
Christos F. Kampolis, MD[2]
Periklis Tomos, MD[2]
Dimosthenis Papapetrou, MD[3]
Ioannis Pantazopoulos, MD[4]
Aikaterini Tzagkaraki, MD[1]
Dimitrios Veldekis, MD[1]
Nikolaos Lolis, MD[1]

[1]Respiratory Intensive Care Unit, 'Sotiria' General Hospital of Athens, Greece,
[2]Second Department of Propaedeutic Surgery, University of Athens Medical School, General Hospital "Laiko", Athens, Greece,
[3]"Iatriko" Hospital, Respiratory Department, P. Faliron, Piraeus, Greece,
[4]4th Respiratory Clinic, 'Sotiria' General Hospital of Athens, Greece

Key words:
- Lung abscess,
- Anaerobic Infection,
- Cavity,
- Percutaneous Drainage,
- Surgical Excision

Correspondence:
Christos F Kampolis
Consultant Pulmonologist
Second Department of Propaedeutic Surgery, General Hospital "Laiko"
17 Ag. Thoma str., 11527, Athens, Greece
Tel.: +302107456883, Fax: +302107456972
E-mail: chkamp77@gmail.com

ABSTRACT. Lung abscesses are usually caused by anaerobic or mixed bacterial infection of the lower respiratory tract. Conservative treatment with broad-spectrum antibiotics is established as the therapy of choice for most patients, with 80-95% responding to antimicrobial therapy. Conservative management failure, manifested by sepsis persistence and/or abscess complications, requires drainage with invasive techniques (percutaneous, endoscopic or surgical) or open surgical removal of the affected lung tissue (segmentectomy, lobectomy or rarely pneumonectomy) in patients with good performance status and sufficient respiratory reserve. Although surgical intervention is accompanied by relatively high mortality rates (11%-28%), it remains the most effective method in preventing complications or future relapses. *Pneumon 2015, 28(1):54-60.*

DEFINITION – PATHOGENESIS

Lung abscess is defined as a localized collection of pus within the lung parenchyma, mostly due to bacterial infection, and is characterized by the presence of a cavity surrounded by necrotic inflammatory lung tissue. Formation of multiple lung abscesses of size less than 2 cm in diameter is commonly referred as 'necrotizing pneumonia'.

Lung abscesses are classified as 'acute' or 'chronic' based on symptom duration (≥ or <4-6 weeks). They are characterized as 'primary' when they appear after lung infection in previously healthy persons or in patients prone to aspiration of nasopharyngeal or oropharyngeal material due to impaired reflexes of cough and swallowing, especially when bad oral hygiene or dental disease (e.g. in alcoholics, drug addicts, patients with reduced level of consciousness, in coma or after epileptic seizures) coexist.[1] Abscess formation may occur 'secondarily' in cases of mechanical bronchial obstruction caused by an endobronchial mass, a foreign body or extraluminar compression, generalized immunosuppression (e.g. HIV infection), septic pulmonary emboli due to infective endocarditis (mostly of the tricuspid valve), possible contamination of bullae or bronchiectases, mediastinal or subphrenic sepsis with direct transdiaphragmatic extension.

Most studies agree that community lung abscesses are mixed infections, whereas dominant pathogens isolated (up to 93% in some patient series[2]) are anaerobic bacteria found in the normal oral and upper intestinal microbial flora (e.g. *Peptostreptococcus, Bacteroides, Prevotella & Fusobacterium spp.*[2–6]). Other less commonly involved pathogens are *Staphylococcus aureus* [occasionally methicillin resistant (MRSA)], *Haemophilus influenzae* (type b and c), *Streptococcus pyogenes, Nocardia* and *Actinomyces* species. In more recent years, higher percentages of aerobic and microaerophilic *Streptococci* (Streptococcus mitis ή mileri)[7,8] and Gram negative bacteria like *Klebsiella pneumoniae* have been identified in Asian populations.[8] Lung abscesses due to hospital-acquired infections caused by Staphylococcus aureus and/or gram (-) bacteria like Pseudomonas and Enterobacter, are mostly met in elderly patients with co-morbidities and/or immunosupression. *Pseudomonas aeruginosa, Staphylococcus aureus* or *Klebsiella pneumoniae* infections have been associated with worse prognosis and higher mortality rates.[9] In addition, patients with variable degrees of immunosupression may present lung abscesses due to opportunistic infections (e.g. fungi, mycobacteria).

CLINICAL MANIFESTATIONS – CHEST IMAGING

Clinical findings of lung abscesses caused by anaerobic or mixed bacteria include non-specific symptoms and signs that last for several weeks and mimic tuberculosis, such as fever with night sweats, dull chest pain, fatigue, anorexia, weight loss and productive cough with fetid and occasionally bloody sputum. On the contrary, when aerobic microorganisms are the responsible pathogens, clinical progression is more rapid and usually results in non-resolving pneumonia.[10] A few years ago (2002), a rapidly progressive clinical condition following viral infection (influenza) was described in younger patients. It was characterized by cardiovascular instability (shock), neutropenia, lung tissue necrosis with abscess formation and high mortality despite antibacterial treatment.[11,12] The responsible isolated pathogen was an MRSA agent with a genome mutation for Panton-Valentine toxin. However, the independent role of the toxin was not verified by experimental models.[13]

Radiological findings consist of solitary or multiple thick-walled cavities with abnormal margins that present either isolated or within a consolidation area. Cavitation occurs when erosion of the lung parenchyma leads to communication with a bronchus, thus resulting in drainage of the necrotic material, entry of air and creation of air-fluid level. Computed tomography (CT) scan has been proven useful in excluding endobronchial obstruction due to malignancy or foreign body and provides additional information about the size and location of the lesion. Furthermore, it enables distinction between lung abscess and empyema. Lung abscess typically presents as a thick-walled round cavity within the lung parenchyma, without pressing on the adjacent bronchi, and forms a sharp angle with the thoracic wall, whereas empyema is lenticular in shape, causes compression of the adjacent parenchyma and forms an obtuse angle with the chest wall.[14]

Other conditions that enter the differential diagnosis of lung cavities include pulmonary infarction, vasculitides, primary or metastatic malignancies, pulmonary sequestration, cystic bronchiectasis and pulmonary cysts with air-fluid level.

MICROBIOLOGICAL DIAGNOSIS – ANTIMICROBIAL TREATMENT

Blood cultures, pleural fluid cultures (if available), bronchial secretion cultures,[15] fiberoptic bronchoscopy with quantitative cultures of samples obtained by protected specimen brush and/or bronchoalveolar lavage (BAL), and cultures of transthoracic needle aspirates are usually required for targeted antimicrobial treatment of lower respiratory infections (pneumonia, abscess). It is advisable to collect each specimen before initiation of any antimicrobial treatment. Cultures of sputa and upper respiratory tract secretions are not suitable for the detection of anaerobic pathogens due to their frequent contamination from normal flora of the oral cavity. Sputum cultures have been proven useful in identifying lung abscesses attributed to aerobic microorganisms such as *Klebsiella spp.*, *Staphylococcus aureus* and *Pseudomonas aeruginosa*. Blood cultures and pleural fluid cultures are usually negative. Generally, bronchoscopic techniques are employed on suspicion of endobronchial obstruction,[16] uncommon pathogens (fungi, mycobacteria, parasites) or immunodeficiency, provided that the physical status of the patient permits it.

Therefore, initial management of lung abscess is based on empirical therapy with broad-spectrum antibiotics, after taking into account the possible risk of multi-drug resistant causative bacteria, and is followed by antibiotic streamlining driven by microbiological documentation as resulted from cultures. Clindamycin (600 mg i.v. every 8 hours followed by 150-300 mg every 6 hours p.o.) is con-

sidered the first-choice antibiotic for therapy of anaerobic lung infections.[17,18] With the emergence of resistance of anaerobic bacteria and microaerophilic *Streptococci* mostly to penicillin G and more rarely to clindamycin, due to β-lactamase production, β-lactam/β-lactamase inhibitor combinations (amoxicillin/clavulanate, ampicillin/sulbactam) presented as highly effective agents for community-acquired lung abscesses.[19,20] This antimicrobial regimen provides adequate coverage against gram (+), gram (-) *Enterobacteriaceae* (e.g. *Klebsiella pneumoniae*, *Enterobacter*) and anaerobic bacteria. A possible therapeutic alternative is the combination of a 2nd (cefuroxime, cefoxitin) or 3rd generation cephalosporin (ceftriaxone) with clindamycin or metronidazole. Monotherapy with metronidazole should be avoided due to inadequate coverage for aerobic and microaerophilic *Streptococci*, such as *Streptococcus milleri*.[4,21,22] Linezolide (initial i.v. administration 600 mg twice daily and subsequent oral administration after clinical improvement) is preferred in cases of lung abscess caused by MRSA.[23] An alternative choice is vancomycin (15 mg/kg x2 i.v., with dose adapted according to optimal serum levels (15-20 mcg/ml) and renal function). Low daptomycin concentrations achieved in lung tissue renders daptomycin inadequate for lower respiratory infections.[24]

Clinical improvement is reflected in the subsidence of fever (within the first 3-4 days) and complete defervescence within 7-10 days.[25] Persistent fever can be explained by treatment failure due to uncommon pathogens (multidrug resistant common bacteria, mycobacteria, fungi) or by the presence of an alternative diagnosis (e.g. endobronchial obstruction, vasculitis) that requires further diagnostic work-up (e.g. bronchoscopy, transdermal or surgical lung biopsy).

The duration of treatment with antibiotics is not widely accepted. According to many experts optimal duration of antimicrobial therapy is 3-6 weeks, whereas others take the timing of radiological response into consideration. In that case, the length of antibiotic treatment depends on complete radiological resolution or stabilization to a small residual lesion. Treatment interval may then be prolonged to several months (more than 2),[6] especially when the initial lesion is of large size (maximum diameter more than 6cm).

DRAINAGE

In the early stages of lung abscess, there exists direct communication of the tracheobronchial tree with the abscess cavity, and therefore purulent material is drained automatically or with the assistance of physiotherapy. However, increased bacterial virulence, insufficient antibiotic concentration inside the abscess cavity and/or a serious underlying respiratory disease may lead to failure of drug treatment.[26] When this occurs, surgical intervention may be considered a definitive therapy, but it is accompanied by relatively high mortality rates (11%-28%).[27] Thus, percutaneous and endoscopic drainage techniques have been gaining ground even as a first-line management, especially for patients who are not candidates for surgery.

Percutaneous drainage

Percutaneous drainage of lung abscesses has been established as treatment of choice for patients who have failed to respond to antibiotic therapy and have an impaired cough reflex (thus resulting in difficult self-drainage of the abscess), and/or are unsuitable for surgical intervention (e.g. due to severe immunodeficiency or mechanical ventilation).[28] However, this technique have demonstrated benefits even in patients without contraindications to surgery. More specifically, 14% of total cases of primary lung abscess (n=48) that were treated by Yellin A et al during a 5-year period (1978-1982) underwent successful percutaneous drainage, without any complications or relapse after 2-5 years of monitoring.[29]

The percutaneous procedure is usually selected for lung abscesses with diameters greater than 4-8 cm and is performed under fluoroscopic, ultrasound or computed tomography guidance. Computed tomography is generally preferred due to additional information provided about location, content and wall-thickness of the abscess. In addition, it has been proven useful in differentiation between empyema and abscess and in exclusion of endobronchial lesions. Either the trocar or the Seldinger technique are used for abscess drainage, with no difference found when evaluating their respective therapeutic effectiveness. The Seldinger technique is considered to be safer since it permits greater control in the positioning of the drainage tube and thus is accompanied by fewer complications.[28,30] Silvermann et al argue that the Seldinger technique increases the risk of pneumothorax, and furthermore, advancing of the guidewire through the thicked-wall abscess may cause bending or rupture of the guidewire or the catheter.[31] The ultimate selection of the procedure depends on the level of training and preferences of the radiologist.

Drainage duration varies but usually 4-5 weeks are required. Chest tubes should not be flushed, in order to

avoid bronchogenic spreading of pus. Drainage according to radiographic findings is successful in up to 83% of cases.[32] Percutaneous drainage failure and indication for surgery may arise when the abscess is multiloculated, organized and/or thick-walled. Technique-related complications occur in nearly 16% of patients. The most significant complications are hemothorax, hemoptysis, pyopneumothorax and fistula formation between the pleural cavity and the abscess resulting in empyema. Less significant complications are those related to bending or leaking of the drainage catheter.

In conclusion, percutaneous drainage of lung abscesses is characterized by high therapeutic effectiveness and preservation of functional lung tissue, is a minimally-invasive method with fewer complications and lower mortality rates (approximately 4%) in comparison to surgical management.[33]

Endoscopic drainage

Percutaneous drainage of lung abscesses should be avoided in cases of coagulation disorders, when a large amount of lung tissue must be traversed or when adjacent anatomical areas hinder direct access to the cavity. Furthermore, the risk for contamination of the pleural space and consequent empyema is not negligible.

In the abovementioned cases, an alternative therapeutic approach is endoscopic drainage of the cavity, a technique described initially by Metras H. and Chapin J. in 1954[34] and subsequently in three publications between 1975 and 1988.[35–37] Until that time, this technique had been performed in a small number of patients with a success rate of approximately 70%. In 2005, Henry F. et al presented a further larger group of patients (n=38), with 100 % successful drainage after catheter placement with a bronchoscope.[38] At first, a guidewire is inserted into the cavity through the working channel of a flexible bronchoscope. Once guidewire location has been ascertained by fluoroscopy, a 7 French pigtail catheter is advanced. If infusion of contrast medium via the catheter confirms its proper positioning, the guidewire and bronchoscope are withdrawn and the catheter tip is stabilized at the nasal wall. Bronchography may be selectively performed to identify the airway that leads into the abscess, thus permitting the insertion of the guidewire via the catheter used for the bronchography. Subsequently, the cavity is flushed daily with normal saline solution through the catheter, while antibiotic infusions (e.g. gentamicin or amphotericin in confirmed fungal infections) may also be administered.[38] The catheter remains open for the rest of the day, thus ensuring the drainage of the abscess.

In a small number of patients with recurrent lung abscesses, endoscopic drainage was performed in combination with laser.[39] The catheter is inserted through a bronchoscope and laser is used in order to perforate the wall of the abscess through the airway and to lead the catheter inside the cavity. The catheter is removed after 4-6 days with immediate improvement of clinical status and radiological imaging within the first 24 hours.

SURGICAL INTERVENTION

Until 1920s, mortality rate from acute lung abscesses was around 75%.[40] The first open surgical drainage was performed by Harold Neuhof, a pioneer of thoracic surgery, and lead to remarkable reduction of morbidity and mortality (2.5%).[41] Percutaneous drainage of lung abscesses was considered as the 'first choice treatment' in the pre-antibiotic era.[42] The discovery of antibiotics (in the late 1940s) rendered conservative drug approach effective in 80-95% of the cases.[43] In the 40s and 50s,[44–47] surgical resection of the involved part of the lung (segmentectomy, lobectomy or rarely pneumonectomy) was acknowledged as the most effective method in preventing complications or relapses, when medical treatment alone failed to cure multiple and/or chronic abscesses. Although 11% of 182 patients that were treated by Hagan & Hardy between 1960 and 1982[1] underwent surgery, total mortality per decade remained unchanged (>20%). The persisting high mortality was attributed to the increased number of patients with co-morbidities such as malignancies and diabetes mellitus and to the administration of immunosuppressive drugs. In a subsequent publication (1986) of a large series of patients by Postma & Le Roux, total mortality was initially comparably high (15.4%) despite surgical resection of the lesions. Mortality was then minimized (0.9%) by restoring the classical technique of "open" surgical drainage and by implementing lung tissue removal only for more complex cases (e.g. large hemoptysis, uncertain diagnosis or lung gangrene).[48]

Patients who are referred to a thoracic surgeon are usually in a serious septic situation due to chronic abscessive lesions not responding to pharmaceutical treatment either alone or combined with transcutaneous drainage. These patients usually present with extensive necrosis of lung parenchyma (abscess size >6 cm), bronchial obstruction due to a mass or a foreign body, empyema, bronchopleural fistula,[40] or infection due to multi-drug resistant microorganisms [e.g. gram(-)]. In most cases,

resection of lung parenchyma is necessary in order to control sepsis.[40,49,50] When a lung abscess is complicated by massive hemoptysis due to rupture of a large blood vessel, immediate surgical resection is indicated.[51] Cavitation in primary lung cancer and pulmonary sequestration complicated by abscess formation are other indications for surgical management.

The extent of surgical resection depends on the size of the underlying lesion. Lobectomy is the most common type of surgical resection required. Segmentectomies are performed in smaller abscesses (<2 cm), whereas a pneumonectomy should be performed at the presence of multiple abscesses or gangrene. The usual surgical approach is thoracotomy. Surgical manipulations may cause cross-contamination of contralateral lung. Placement of a double-lumen endotracheal tube, prone positioning of the patient and artificial obstruction of the main bronchus before removing the abscess are the usual measures for preventing cross-contamination. In addition, bronchial stump reinforcement with a pedicled intercostal muscle flap or other highly vascular tissue may prevent the formation of a bronchopleural fistula. When the chronic inflammatory process of pulmonary infection causes incomplete re-expansion of the remaining lobes, it is quite possible that a portion of the pleural space will remain empty. Some thoracic surgeons recommend filling that space with a large pedicled ipsilateral latissimus dorsi muscle flap or omentum.

Surgical debridement followed by immediate filling of the cavity with a flap of highly vascular soft tissue, or debridement and cavity fistulization into the pleural space followed by drainage by means of a chest tube are proposed when conservative measures fail to control sepsis and poor performance status prohibits more extensive surgery (lobectomy or pneumonectomy), provided that a limited thoracotomy is feasible (Figure 1, Panels A to C). When thoracotomy is contraindicated, open surgical drainage may be required either by creating a cavernostomy[52] or a pouch-like cavity communicating with the thoracic wall through limited rib resection. Finally, a thoracoscopic technique (Video assisted thoracoscopic surgery: VATS) for abscess debridement and drainage has been effectively implemented in a small number of paediatric patients.[53]

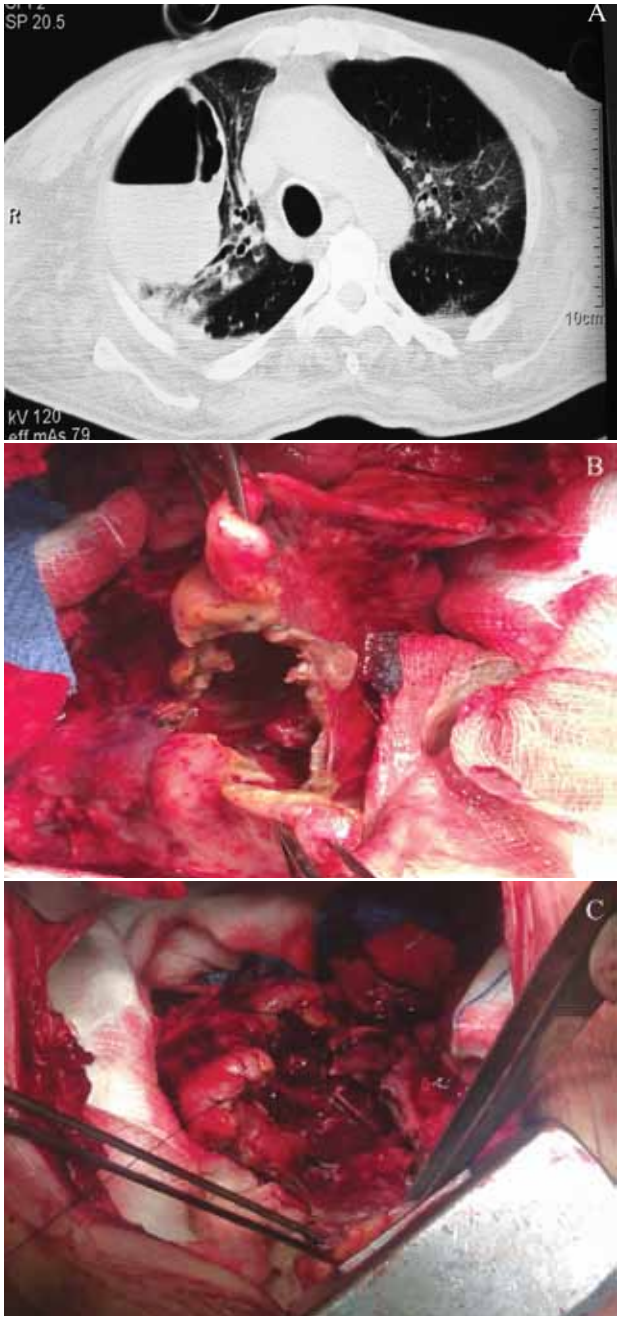

FIGURE 1. Surgical drainage was indicated in the case of a 68-year-old patient with a large-sized right middle lobe abscess (A), persistence of radiological findings and isolation of a multidrug resistant gram (-) microbe in sputa. Decreased spirometric indices prohibited anatomic resection of the lesion. The pulmonary cavity was initially drained and a section of the cavity dome was removed (B). Tissue edges were then approximated with sutures and cavity drainage was maintained by direct fistulization into the pleural space (C). [*Images were offered by Dr. P. Tomos, Assistant Professor in Thoracic Surgery (Second Department of Propaedeutic Surgery, Athens, Greece)*].

CONCLUSIONS

Discovery of novel antimicrobial agents during the 40s, radically modified management and outcome (mortality

>70% up to then) of lung abscesses. Currently, antibiotics are the cornerstone for the treatment for lung abscesses and most patients (80-95%) respond to antimicrobial therapy. Failure of conservative management, manifested by sepsis persistence and/or abscess complications, may necessitate drainage with invasive techniques (percutaneous, endoscopic or surgical) or open surgical removal of the lung lesion in patients with good performance status and sufficient respiratory reserve.

CONFLICTS OF INTEREST-FINANCIAL SOURCES

None.

REFERENCES

1. Hagan JL, Hardy JD. Lung abscess revisited. A survey of 184 cases. Ann Surg 1983;197:755–62.
2. Bartlett JG, Finegold SM. Anaerobic infections of the lung and pleural space. Am Rev Respir Dis 1974;110:56–77.
3. Mori T, Ebe T, Takahashi M, Isonuma H, Ikemoto H, Oguri T. Lung abscess: analysis of 66 cases from 1979 to 1991. Intern Med 1993;32:278–84.
4. Bartlett JG. The role of anaerobic bacteria in lung abscess. Clin Infect Dis 2005;40:923–5.
5. Bartlett JG. Anaerobic bacterial infections of the lung. Chest 1987;91:901–9.
6. Bartlett JG. Anaerobic bacterial infections of the lung and pleural space. Clin Infect Dis 1993;16 Suppl 4:S248–55.
7. Takayanagi N, Kagiyama N, Ishiguro T, Tokunaga D, Sugita Y. Etiology and outcome of community-acquired lung abscess. Respiration 2010;80:98–105.
8. Wang J-L, Chen K-Y, Fang C-T, Hsueh P-R, Yang P-C, Chang S-C. Changing bacteriology of adult community-acquired lung abscess in Taiwan: Klebsiella pneumoniae versus anaerobes. Clin Infect Dis 2005;40:915–22.
9. Hirshberg B, Sklair-Levi M, Nir-Paz R, Ben-Sira L, Krivoruk V, Kramer MR. Factors predicting mortality of patients with lung abscess. Chest 1999;115:746–50.
10. Davis B, Systrom DM. Lung abscess: pathogenesis, diagnosis and treatment. Curr Clin Top Infect Dis 1998;18:252–73.
11. Gillet Y, Issartel B, Vanhems P, et al. Association between Staphylococcus aureus strains carrying gene for Panton-Valentine leukocidin and highly lethal necrotising pneumonia in young immunocompetent patients. Lancet 2002;359:753–9.
12. Francis JS, Doherty MC, Lopatin U, et al. Severe community-onset pneumonia in healthy adults caused by methicillin-resistant Staphylococcus aureus carrying the Panton-Valentine leukocidin genes. Clin Infect Dis 2005;40:100–7.
13. Bubeck Wardenburg J, Palazzolo-Ballance AM, Otto M, Schneewind O, DeLeo FR. Panton-Valentine leukocidin is not a virulence determinant in murine models of community-associated methicillin-resistant Staphylococcus aureus disease. J Infect Dis 2008;198:1166–70.
14. Stark DD, Federle MP, Goodman PC, Podrasky AE, Webb WR. Differentiating lung abscess and empyema: radiography and computed tomography. AJR Am J Roentgenol 1983;141:163–7.
15. Bartlett JG. Diagnostic accuracy of transtracheal aspiration bacteriologic studies. Am Rev Respir Dis 1977;115:777–82.
16. Sosenko A, Glassroth J. Fiberoptic bronchoscopy in the evaluation of lung abscesses. Chest 1985;87:489–94.
17. Levison ME, Mangura CT, Lorber B, et al. Clindamycin compared with penicillin for the treatment of anaerobic lung abscess. Ann Intern Med 1983;98:466–71.
18. Gudiol F, Manresa F, Pallares R, et al. Clindamycin vs penicillin for anaerobic lung infections. High rate of penicillin failures associated with penicillin-resistant Bacteroides melaninogenicus. Arch Intern Med 1990;150:2525–9.
19. Germaud P, Poirier J, Jacqueme P, et al. [Monotherapy using amoxicillin/clavulanic acid as treatment of first choice in community-acquired lung abscess. Apropos of 57 cases]. Rev Pneumol Clin 1993;49:137–41.
20. Fernández-Sabé N, Carratalà J, Dorca J, et al. Efficacy and safety of sequential amoxicillin-clavulanate in the treatment of anaerobic lung infections. Eur J Clin Microbiol Infect Dis 2003;22:185–7.
21. Eykyn SJ. The therapeutic use of metronidazole in anaerobic infection: six years' experience in a London hospital. Surgery 1983;93:209–14.
22. Perlino CA. Metronidazole vs clindamycin treatment of anerobic pulmonary infection. Failure of metronidazole therapy. Arch Intern Med 1981;141:1424–7.
23. Wunderink RG, Niederman MS, Kollef MH, et al. Linezolid in methicillin-resistant Staphylococcus aureus nosocomial pneumonia: a randomized, controlled study. Clin Infect Dis 2012;54:621–9.
24. DeLeo FR, Otto M, Kreiswirth BN, Chambers HF. Community-associated meticillin-resistant Staphylococcus aureus. Lancet 2010;375:1557–68.
25. Bartlett JG, Gorbach SL, Tally FP, Finegold SM. Bacteriology and treatment of primary lung abscess. Am Rev Respir Dis 1974;109:510–8.
26. Mwandumba HC, Beeching NJ. Pyogenic lung infections: factors for predicting clinical outcome of lung abscess and thoracic empyema. Curr Opin Pulm Med 2000;6:234–9.
27. Alifano M, Gaucher S, Rabbat A, et al. Alternatives to resectional surgery for infectious disease of the lung: from embolization to thoracoplasty. Thorac Surg Clin 2012;22:413–29.
28. vanSonnenberg E, D'Agostino HB, Casola G, Wittich GR, Varney RR, Harker C. Lung abscess: CT-guided drainage. Radiology 1991;178:347–51.
29. Yellin A, Yellin EO, Lieberman Y. Percutaneous tube drainage: the treatment of choice for refractory lung abscess. Ann Thorac Surg 1985;39:266–70.
30. Erasmus JJ, McAdams HP, Rossi S, Kelley MJ. Percutaneous management of intrapulmonary air and fluid collections. Radiol Clin North Am 2000;38:385–93.
31. Silverman SG, Mueller PR, Saini S, et al. Thoracic empyema: management with image-guided catheter drainage. Radiol-

ogy 1988;169:5–9.
32. Kelogrigoris M, Tsagouli P, Stathopoulos K, Tsagaridou I, Thanos L. CT-guided percutaneous drainage of lung abscesses: review of 40 cases. JBR-BTR 2011;94:191–5.
33. Wali SO, Shugaeri A, Samman YS, Abdelaziz M. Percutaneous drainage of pyogenic lung abscess. Scand J Infect Dis 2002;34:673–9.
34. Metras H, Charpin J. Lung abscess and bronchial catheterization. J Thorac Surg 1954;27:157–72.
35. Connors JP, Roper CL, Ferguson TB. Transbronchial catheterization of pulmonary abscesses. Ann Thorac Surg 1975;19:254–60.
36. Rowe LD, Keane WM, Jafek BW, Atkins JP. Transbronchial drainage of pulmonary abscesses with the flexible fiberoptic bronchoscope. Laryngoscope 1979;89:122–8.
37. Schmitt GS, Ohar JM, Kanter KR, Naunheim KS. Indwelling transbronchial catheter drainage of pulmonary abscess. Ann Thorac Surg 1988;45:43–7.
38. Herth F, Ernst A, Becker HD. Endoscopic drainage of lung abscesses: technique and outcome. Chest 2005;127:1378–81.
39. Shlomi D, Kramer MR, Fuks L, Peled N, Shitrit D. Endobronchial drainage of lung abscess: the use of laser. Scand J Infect Dis 2010;42:65–8.
40. Schweigert M, Dubecz A, Stadlhuber RJ, Stein HJ. Modern history of surgical management of lung abscess: from Harold Neuhof to current concepts. Ann Thorac Surg 2011;92:2293–7.
41. Neuhof H, Hurwitt E. Acute putrid abscess of the lung: VII. Relationship of the thechnic of the one-stage operation to results. Ann Surg 1943;118:656–64.
42. Monaldi V. Endocavitary aspiration in the treatment of lung abscess. Dis Chest 1956;29:193–201.
43. Wali SO. An update on the drainage of pyogenic lung abscesses. Ann Thorac Med 2012;7:3–7.
44. Neuhof H, Touroff AS, Aufses AH. The surgical treatment, by drainage, of subacute and chronic putrid abscess of the lung. Ann Surg 1941;113:209–20.
45. Shaw RR, Paulson DL. Pulmonary resection for chronic abscess of the lung. J Thorac Surg 1948;17:514–22.
46. Myers RT, Bradshaw HH. Conservative resection of chronic lung abscess. Ann Surg 1950;131:985–93.
47. Waterman DH, Domm SE. Changing trends in the treatment of lung abscess. Dis Chest 1954;25:40–53.
48. Postma MH, le Roux BT. The place of external drainage in the management of lung abscess. S Afr J Surg 1986;24:156–8.
49. Refaely Y, Weissberg D. Gangrene of the lung: treatment in two stages. Ann Thorac Surg 1997;64:970–3; discussion 973–4.
50. Chen C-H, Huang W-C, Chen T-Y, Hung T-T, Liu H-C, Chen C-H. Massive necrotizing pneumonia with pulmonary gangrene. Ann Thorac Surg 2009;87:310–1.
51. Philpott NJ, Woodhead MA, Wilson AG, Millard FJ. Lung abscess: a neglected cause of life threatening haemoptysis. Thorax 1993;48:674–5.
52. Nakada T, Akiba T, Inagaki T, Morikawa T, Ohki T. Simplified cavernostomy using wound protector for complex pulmonary aspergilloma. Ann Thorac Surg 2014;98:360–1.
53. Nagasawa KK, Johnson SM. Thoracoscopic treatment of pediatric lung abscesses. J Pediatr Surg 2010;45:574–8.