

Figure S1. Fixed UAO

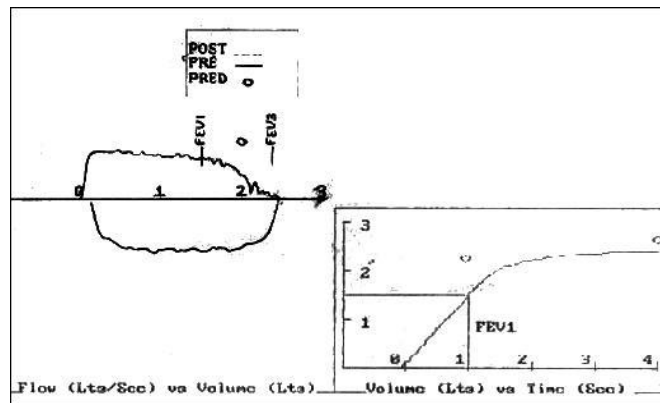


Figure S2. Variable intrathoracic UAO

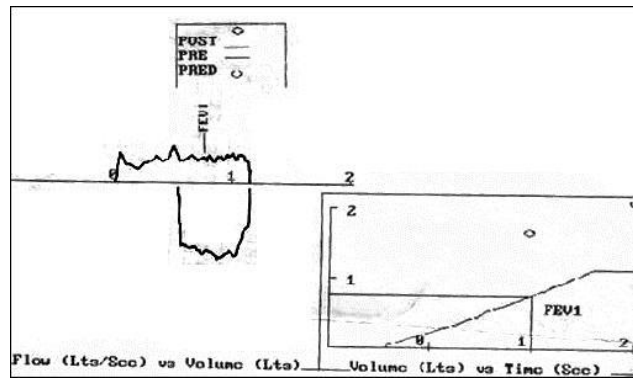


Figure S3. Variable extrathoracic UAO due to goiter aggravating in supine position

