

Mucoviscidosis and pulmonary tuberculosis

Petru Emil Muntean, MD

Department of Pulmonology,
Campeni Chronic Diseases Hospital,
Campeni City, Alba County,
Romania

Key words:

- AFB
- Cystic fibrosis
- Genotyping
- GeneXpert MTB/RIF assay
- MTB

Correspondence:

Petru Emil Muntean
Str. 1 Decembrie 1918, P.C. 405100
Campia Turzii, Cluj County, Romania
Tel.: +40751476432
e-mail: muntean.petruemil@yahoo.com

A nineteen-year-old caucasian male, chronic smoker (>20 cig/day), diagnosed with mucoviscidosis at the age of 4 years old, was admitted with a two week history of fevers, night sweats, coughing up blood, severe chest pain, worsening cough and 10 kilograms weight loss. Acid fast bacilli cultures revealed no growth and sputum cultures had grown *Pseudomonas aeruginosa*. His forced vital capacity and forced expiratory volume had dropped to 55% and 40% of predicted volumes. Vital signs revealed Oxygen saturation 78%, a pulse rate of 100 beats per minute, high temperature (over 39 degrees celsius) and a respiratory rate of 26 breaths per minute. On clinical examination: yellow teeth, an ill-appearing thin male with increased work of breathing and bilateral coarse rhonchorous breath sounds. Laboratory results

showed leukocytosis (14,000/mm³), hepatic cytolysis (slightly aminotransferases increase) and C-reactive protein concentrations were elevated (≥ 10 mg/L). Admission chest radiograph (Figure 1) and computed tomography chest (Figure 2) revealed severe chronic lung disease with a generalized irregular thickening of linear markings throughout the lungs, invariable hyperinflation, bronchiectasis, multiple bilateral cavitary lesions, multiple small cysts superimposed on diffuse, coarse, reticular pattern. Initially the patient received oxygen therapy, symptomatic treatment and broad spectrum antibiotics without significant clinical improvement even after one month of treatment. By that time, the subsequent cultures grew mycobacterium tuberculosis, which was sensitive to all first line tuberculosis drugs. Due to recent development and based on the national protocol¹, the patient was initiated on a weight-based dosing of 4 drug antituberculous regimen: isoniazid, rifampicin, ethambutol and pyrazinamide. Human immunodeficiency virus status negative. After 2 weeks the patient had clinical improvement with resolution of his hemoptysis, chronic cough and febrile episodes. After daily-use of hypertonic saline (sterilized, extra-salty water) he has shown better mucus clearance along with an increase in his weight, forced vital capacity and forced expiratory volume had improved to 80% and 68% of predicted volumes, respectively. After he was cured of tuberculosis, he was referred to a specialized center in cystic fibrosis.

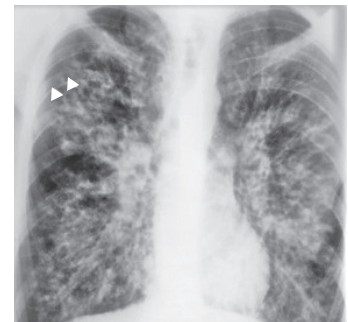


FIGURE 1. Chest radiograph.

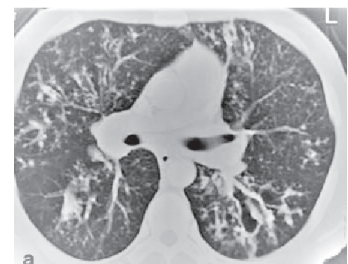

FIGURE 2. Computed tomography scan.

REFERENCE:

1. http://old.ms.ro/documente/GHID%20Metodologic%20de%20implementare%20a%20Programului%20national%20de%20prevenire,%20supraveghere%20si%20control%20al%20tuberculozei%202015_15424_18333.pdf.