

Pneumothorax

Unnati D. Desai¹, MD
 Vinaya Karkhanis², MD
 Jyotsna M. Joshi³, MD

¹Associate Professor

²Late Additional Professor

³Professor and Head

Department of Pulmonary Medicine,
 TN Medical College and BYL Nair Hospital,
 Mumbai, India

Key words:

- Spontaneous
- Traumatic
- Pigtail
- Bronchopleural fistula

ABSTRACT

Itardvin coined the term pneumothorax in the year 1803 and Laennec described its clinical features in 1819. It is defined as the presence of air or gas in the pleural cavity. Pneumothorax can be primary or secondary depending on underlying lung condition. This can be further classified as spontaneous, iatrogenic and traumatic. Primary spontaneous pneumothorax described by Kjaergard in 1932; occurs in people without underlying lung disease and in the absence of an inciting event. Secondary spontaneous pneumothorax (SSP) occurs in people with a wide variety of parenchymal lung diseases. Occasionally, the amount of air in the chest increases markedly when a one-way valve is formed by an area of damaged tissue leading to a tension pneumothorax and can present as a medical emergency. Symptoms are related to the amount of air present in the pleural cavity and underlying etiology. They typically include chest pain and shortness of breath. Diagnosis by physical examination alone can be difficult or inconclusive particularly in smaller pneumothoraces and X-ray chest or computed tomography (CT) scan is usually used to confirm its presence. Small spontaneous pneumothoraces typically resolve without treatment and require only monitoring. Larger pneumothoraces where patients are symptomatic needs intervention with simple needle aspiration, pigtail catheterization or intercostal drainage tubes.

Pneumon 2019, 32(4):144-154.

INTRODUCTION

The term pneumothorax was first coined by Itardvin, a student of Laennec in 1803 and its clinical features are described by Laennec in 1819. It is defined as the presence of air or gas in the pleural space. Symptoms are related to the quantity of pneumothorax and the underlying etiology. They typically include **chest pain and shortness of breath. Diagnosis by physical examination** alone can be **difficult or inconclusive** particularly in smaller pneumothoraces and X-ray chest (CXR) or computed tomography (CT) is usually used to confirm its presence. Small spontaneous pneumo-

Correspondence to:

Dr. Jyotsna M. Joshi, MD, Professor and Head
 Department of Pulmonary Medicine, OPD bldg,
 TN Medical College & BYL Nair Hospital,
 AL Nair Road, Mumbai Central,
 Mumbai - 400008, India
 Tel.: +2223003095
 E-mail: drjoshijm@gmail.com

thoraces typically resolve without treatment and require only monitoring. Larger pneumothoraces where patients are symptomatic need intervention with simple needle aspiration, pigtail catheterization or intercostal drainage tubes. Bronchopleural fistula can be considered a special case of complicated persistent pneumothorax, representing a challenging management problem associated with significant morbidity and even mortality.

TYPES OF PNEUMOTHORAX (Chart 1)

Air may leak from lung to pleural space in three situations: (1) arising spontaneously by alveolar rupture; (2) introduced following trauma; (3) generated by gas forming organisms. Accordingly pneumothorax can be spontaneous and non-spontaneous. Spontaneous pneumothoraces occur without any preceding trauma or obvious precipitating causes. It is classified as primary or secondary. Primary spontaneous pneumothorax described by Kjaergard in 1932; occurs in people without underlying lung disease and in the absence of any inciting event.¹ Secondary spontaneous pneumothorax (SSP) occurs in patients with pre-existing lung diseases such as COPD, cystic fibrosis, or pneumocystis carinii pneumonia.² Non-spontaneous pneumothoraces are also known as traumatic and are subdivided into non-iatrogenic and iatrogenic. Non-iatrogenic pneumothoraces can develop following direct or indirect trauma, such as penetrating or blunt trauma to the chest, with air entering the pleural space directly through the chest wall; visceral pleural penetration; or alveolar rupture due to sudden compression

of the chest. Iatrogenic pneumothorax results from a complication of diagnostic or therapeutic intervention.³ Common causes of primary and secondary spontaneous pneumothorax are enumerated in Table 1.

SPONTANEOUS PNEUMOTHORAX

Spontaneous pneumothorax remains a significant health problem because the recurrence rate is estimated to be approximately 10%-20%, even after surgical management is performed.⁴ Spontaneous pneumothoraces, which occur in the absence of thoracic trauma, are classified as primary or secondary.⁵ A primary spontaneous pneumothorax (PSP) is a pneumothorax that occurs without a precipitating event in a person who does not have any known lung disease. The incidence of primary spontaneous pneumothorax (PSP) in men varies geographically, from 7.4 per 100,000 population per year in the United States to 37 per 100,000 population per year in the United Kingdom. The incidence is substantially less in women than in men, ranging from 1.2 per 100,000 population per year in the United States to 15.4 per 100,000 population per year in the United Kingdom.⁶ Primary spontaneous pneumothoraces usually occurs in tall, thin men between the ages of 20 and 30 years. Smoking increases a healthy male's lifetime risk of developing a pneumothorax from 0.1 to 12%. Height is thought to be a risk factor because the pleural pressure gradient increases from the base to the apex of the lung. Consequently, apical alveoli in taller patients are subject to far greater distending pressures, which may precipitate subpleural cyst formation.⁷

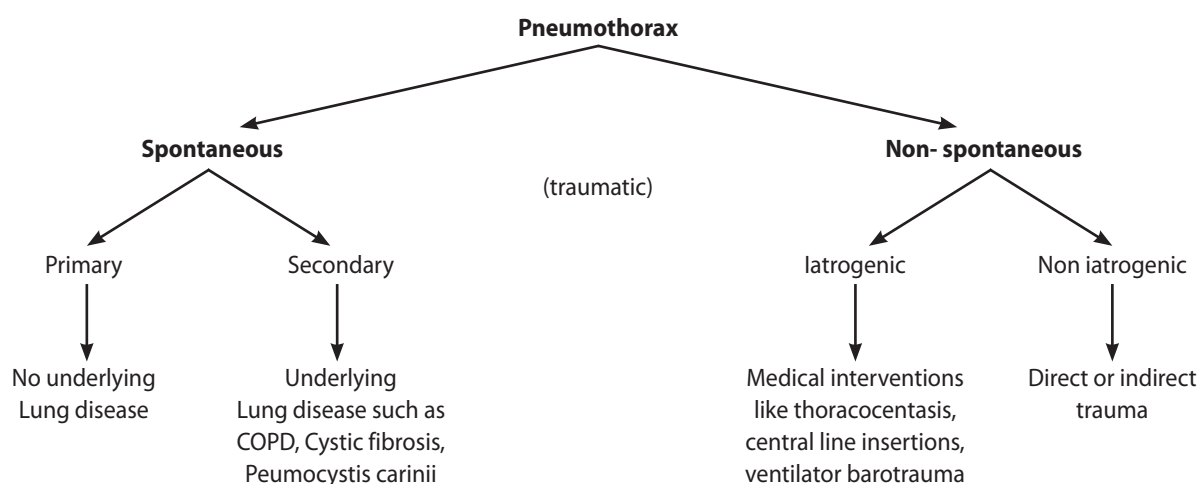


CHART 1. Classification of pneumothorax.

TABLE 1. Causes of pneumothorax

Common causes of Pneumothorax	
Primary spontaneous	Sub pleural Blebs
Secondary spontaneous	
Airway diseases	COPD Cystic fibrosis Status asthmaticus
Infection	Necrotising pneumonias Granulomas
Neoplastic diseases	Carcinoma with ball valve obstruction Secondary to bronchial obstruction Tumor necrosis due to cytotoxic or radiation therapy
Interstitial lung diseases	Idiopathic pulmonary fibrosis NSIP Histiocytosis X Lymphangiomyomatosis Dube syndrome Sarcoidosis Pneumoconiosis
Connective tissue disease	Rheumatoid arthritis scleroderma ankylosing spondylitis Marfan's syndrome Ehlers Danlos syndrome
Iatrogenic	Central venous catheterization Thoracocentesis, pleural biopsy Transthoracic, transbronchial biopsies Intercostal block Use of high PEEP
Non iatrogenic	Blunt and penetrating injuries such as Rib fracture Rupture of bleb, Rupture of bronchus, lung tear

Male gender, tall stature, low body weight, and failure to stop smoking have been associated with an increased risk of recurrence.⁸ The risk of recurrence is reduced in patients who undergo chemical pleurodesis. Secondary spontaneous pneumothorax (SSP) occurs in patients with pre-existing lung disease such as chronic obstructive pulmonary disease (COPD), cystic fibrosis, or Pneumo-

cystis carinii pneumonia. Due to the underlying lung disease, they can present with compromised respiratory reserves and can be life threatening also.⁹ The diagnosis can usually be made on CXR, however CT is sometimes necessary to differentiate pneumothoraces from large thin-walled bullae.¹⁰

NON-SPONTANEOUS/TRAUMATIC PNEUMOTHORAX

They occur due to trauma which is either non-iatrogenic or iatrogenic in nature. A non-iatrogenic traumatic pneumothorax can result from either penetrating or non-penetrating chest trauma.¹¹ With penetrating chest trauma; the wound allows air to enter the pleural space via the chest wall or via the visceral pleura from the tracheobronchial tree. With non-penetrating trauma, a pneumothorax may develop if the visceral pleura is lacerated secondary to a rib fracture or dislocation. In the majority of patients with pneumothorax secondary to non-penetrating trauma, however, there are no associated rib fractures. It is thought that the sudden chest compression abruptly increases the alveolar pressure, which may cause alveolar rupture. Air then enters the interstitial space and dissects toward either the visceral pleura or the mediastinum to produce mediastinal emphysema. A pneumothorax results when either the visceral or mediastinal pleura ruptures. The incidence of iatrogenic traumatic pneumothorax is also high. In a study of 3430 patients in 12 intensive care units in France, 3.0% developed a pneumothorax. The etiologies of the pneumothoraces in this study were mechanical ventilation in 42, central venous catheters in 28, thoracocentesis in 21, and miscellaneous in 3.¹² Currently, the leading cause of iatrogenic pneumothorax is transthoracic needle aspiration. The incidence of iatrogenic pneumothorax with this procedure is about 25%, and about 10% of the patients with pneumothorax receive tube thoracostomy.¹³ This procedure is more likely to result in a pneumothorax if the patient has COPD, if the lesion is deep within the lung, or if the angle of the needle route is wide.¹⁴

Pneumothorax is also classified as closed, open, and valvular based on the pathology. In a closed pneumothorax the communication between the pleura and lung seals off as the lung collapses and does not reopen. Pleural pressures remain negative and air is gradually reabsorbed. An open pneumothorax has a persistent 'air leak.' Pleural pressures equal atmospheric pressure and

lung cannot re-expand. The term open is also applied to pneumothorax resulting from penetrating wound of the chest wall. A valvular pneumothorax occurs when the communication between the pleura and lung persists, but is small and act as a one-way valve, which allows air to enter during inspiration but prevents it from escaping during expiration. Tension pneumothorax usually results and pleural pressures are always positive.

Other types of pneumothorax described in literature are as follows. Tension pneumothorax is a pneumothorax complicated by cardio respiratory embarrassment due to decreased cardiac output. There will be mediastinal shift to opposite side. The intrapleural pressure exceeds atmospheric pressure throughout expiration and often during inspiration as well. Patients present with tachycardia, tachypnea, cyanosis, diaphoresis and marked hypoxemia with respiratory alkalosis or acidosis. A pneumothorax may be associated with a bronchopleural fistula. Bronchopleural fistulas (BPFs) are communications between the bronchial tree and the pleural space. They represent a challenging management problem and are associated with significant morbidity and even mortality. The term bronchopleural fistula is often used synonymously with open pneumothorax or 'persistent air leak' but constitutes a distinct clinical entity. A large bronchopleural fistula facilitates transmission of infection from air passages into the pleural space and empyema results. Some use terminologies as alveolar pleural fistula (APF) and bronchopleural fistula (BPF). APF (synonym: parenchymal-pleural fistulae), defined as persistent air leak for more than 24 hours after the development of an abnormal communication between the pulmonary parenchyma distal to a segmental bronchus and the pleural space. This is best distinguished from a BPF, which is a communication between the lobar or segmental bronchi and the pleural space, since aetiology and management are different.¹⁵ BPF presents with cough, copious purulent sputum and amphoric bronchial breath sounds on auscultation. Methylene blue injected in the pleural space is seen in the expectorated sputum (methylene blue test). CT with maximum intensity projection (MIP) images help to identify presence of BPF. The term complicated pneumothorax is suggested for pneumothorax with fluid (hydropneumothorax), pus (pyopneumothorax) or blood (haemopneumothorax). All these conditions require chest drainage as an initial management. A chronic pneumothorax results from formation of 'pleural peel' due to associated empyema and a persistent air leak. With increasing utilization of advanced radioimaging an

entity called occult pneumothorax has been defined. It is a pneumothorax that was not suspected clinically nor was evident on the plain radiograph but rather identified on computed tomography scan.

CLINICAL PRESENTATION

Pleuritic chest pain and dyspnoea are main symptoms. In patients with underlying lung disease, dyspnoea is severe and significant hypoxaemia can occur, even with a small pneumothorax. Arterial blood gas measurements typically show an increase in the alveolar-arterial oxygen gradient and acute respiratory alkalosis. Patients with a small pneumothorax (<15% of the hemithorax) often have a normal physical finding on examination. Tachycardia is the most common physical finding. In patients with a larger pneumothorax, examination shows decreased movement of the chest, a hyper-resonant percussion note, tracheal shift to opposite side, and decreased or absent breath sounds on the affected side. Coin test can be demonstrated. The physical findings are often subtle and may be masked by the underlying lung disease, particularly in patients with COPD. Pneumothorax may be associated with complications (Table 2). In case of a tension pneumothorax, there will be cardio respiratory embarrassment; BPF/large pneumothorax is associated with amphoric bronchial breath sounds on auscultation. A hydropneumothorax may have the signs denoted by 4S i.e. straight line dullness, shifting dullness, succussion splash and sound of coin percussion. Associated mediastinal emphysema (pneumomediastinum) can cause subcutaneous emphysema, palpable crepitus and Hamman's sign. It is characterized by precordial systolic crepitations and diminution of heart sounds.

TABLE 2. Complications of pneumothorax

Complications of pneumothorax

Tension pneumothorax
Mediastinal emphysema
Bronchopleural fistula
Chronic pneumothorax
Loculated pneumothorax
Pyopneumothorax
Persistent air leak
Re-expansion pulmonary edema

RADIOLOGY

Various radiodiagnostics helps in diagnosis and management of pneumothorax. The diagnosis of pneumothorax can be confirmed in the majority of cases on an CXR –Postero-Anterior (PA) view (Figure 1) which also allows an estimation of the pneumothorax size.¹⁶ Air in the pleural space accumulates in the highest part of the thoracic cavity because air is less dense than the lung. A definitive radiologic diagnosis of pneumothorax can only be made when a visceral pleural line is evident as a faint but sharply defined line separating the lung parenchyma from the remainder of the thoracic cavity, which is clear and devoid of lung markings. An enlarged hemithorax, a depressed diaphragm, and a shifted mediastinum do not mean that a tension pneumothorax is present. In case of small pneumothoraces full expiratory film can be obtained in upright position. With full expiration the lung volume is reduced, and therefore the percentage of the hemithorax occupied by air increases, making identification of the visceral line much easier. Another option is to obtain lateral decubitus film with the side of the suspected pneumothorax superior. This increases the distance between the lung and the chest wall. Chronic lung conditions give rise to adhesions between parietal and visceral pleura restricting lung collapse. In such situations, a pneumothorax may be loculated and localized rather than spreading throughout the pleural space; thus altering the radiologic appearance of pneumothoraces (Figure 2). Both the BTS and ACCP guidelines divide

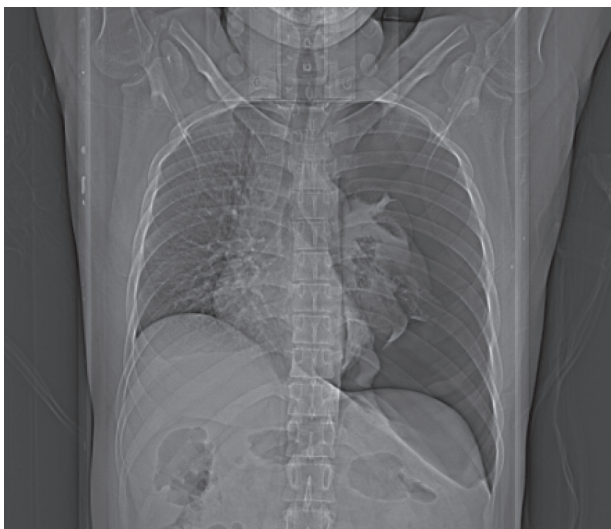


FIGURE 1. X-ray chest postero-anterior view showing pneumothorax.

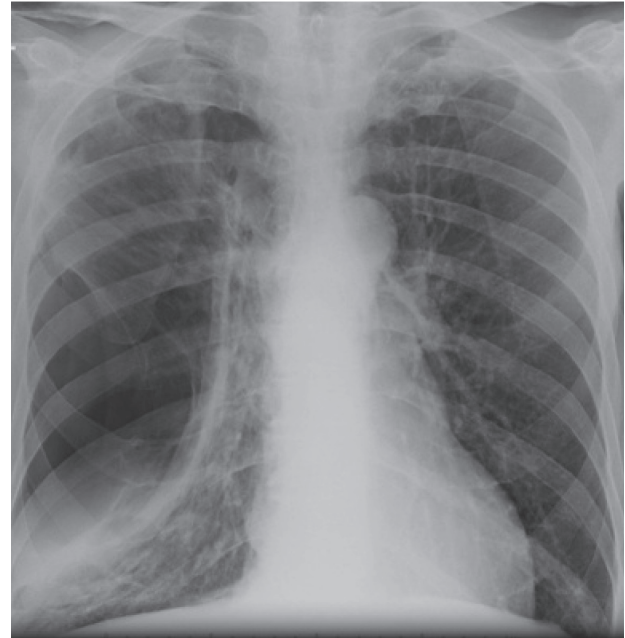


FIGURE 2. X-ray chest postero-anterior view showing loculated pneumothorax.

pneumothoraces into small or large depending on the degree of lung collapse; however, they differ in their absolute definition. The BTS guidelines state that a 2 cm radiographic pneumothorax extending throughout the lung field on a CXR-PA occupies approximately 50% of the hemithorax. When the visible rim between the lung margin and the chest wall is less than 2 cm the pneumothorax is defined as small, and when the rim is greater than 2 cm it is termed large. The ACCP define a pneumothorax as small when the distance from apex to cupola is less than 3 cm, and large when the distance is greater than 3 cm.¹⁷ Ultrasonography has been shown to have high sensitivity (95%), specificity (100%), and diagnostic effectiveness (98%) for pneumothorax when compared with CT as a standard. It is useful for detecting small collections not seen on plain films and the extent of the air collection can be estimated by tracking the presence of the 'sliding lung sign' over the chest wall. Experience in the use of ultrasound for this indication is required to be confident in its application. It is difficult or impossible to visualize pleural structures with ultrasound through surgical emphysema. A typical 'comet tailing' phenomenon of the movement of the lung tissue against the pleura during respiration can be seen in bullous disease, but is absent when the lung is collapsed as in pneumothorax.¹⁸

CT thorax (Figure 3) is gold standard for confirmation

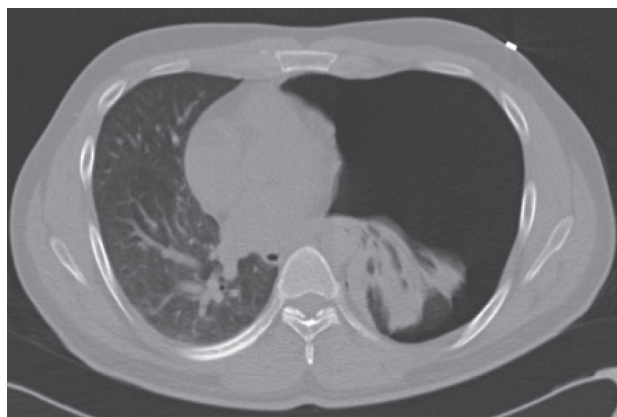

FIGURE 3. Computed Tomography thorax showing pneumothorax.

of a pneumothorax. It also differentiates a pneumothorax from complex bullous lung disease; when aberrant chest tube placement is suspected. It allows definitive diagnosis of other pleural and lung pathologies and should be considered early when doubt exists. CT scanning is regarded as the best means of establishing the size of a pneumothorax.¹⁹ CT also help in distinction of pneumothorax from emphysematous bullae. The bullae of emphysema can be very large and, when situated in the periphery of the lung, can mimic a loculated pneumothorax. A chest drain inserted into a bulla in the mistaken belief that it is a pneumothorax is not uncommon. The lack of a lung edge, the round nature of the bulla, and the presence of multiple bullae elsewhere in the lung are all clues to the diagnosis. In difficult cases, CT is helpful in distinguishing between the two. The double wall sign is a valuable sign to help distinguish a pneumothorax from adjacent giant bulla²⁰ (Figure 4). This sign occurs due to the air outlining both sides of the bulla wall parallel to the chest wall. Another classical differential diagnosis not be missed is air-filled stomach or bowel in the chest secondary to diaphragmatic hernia. Ventilation scintigraphy can be used to localize the air leak in patients presenting with persistent air leak.²¹

MEASUREMENT OF PNEUMOTHORAX (Figure 5a, b, c)

The size of a pneumothorax, in terms of volume is difficult to assess accurately from a chest radiograph which is a two dimensional image. In 1993 guidelines pneumothorax was classified into 3 groups: 1) Small: A

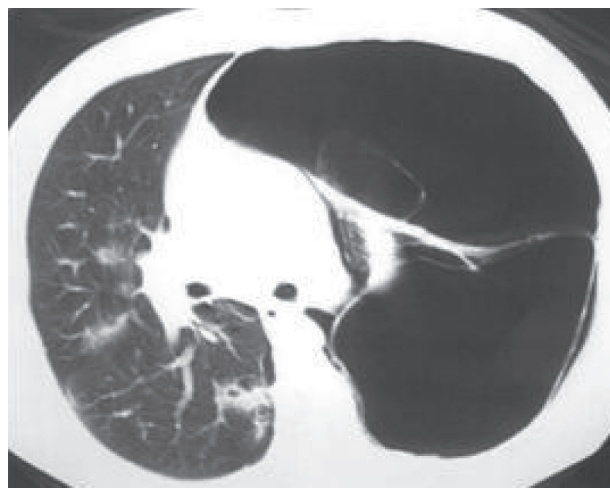


FIGURE 4. Computed Tomography thorax showing double wall sign with bulla.

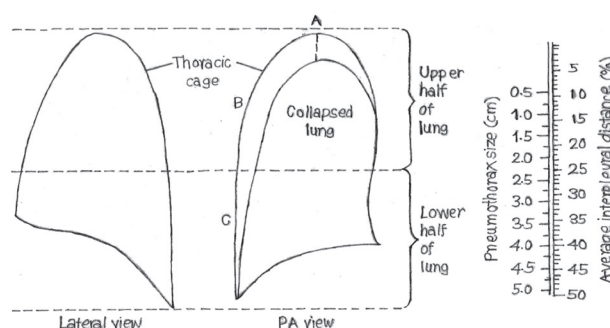


FIGURE 5A. Measurement of pneumothorax.

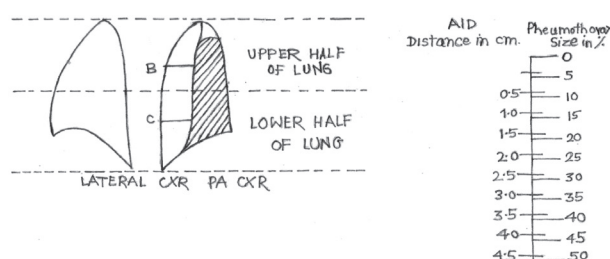


FIGURE 5B. Measurement of pneumothorax.

small rim of air around the lung, 2) Moderate: Lung collapsed half way towards the heart border, 3) Complete: Airless lung, separate from the diaphragm. The volume of pneumothorax approximates to the ratio of the cube of the lung diameter to the hemithorax diameter. Thus, one can estimate the degree of collapse by measuring an average diameter of the lung and the hemithorax,

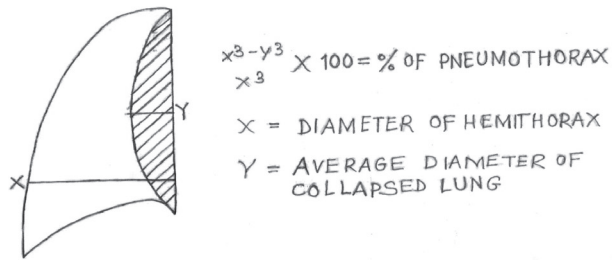


FIGURE 5C. Measurement of Pneumothorax.

cubing these diameters, and finding the ratios. For example, a pneumothorax of 1 cm on CXR-PA film occupies about 27% of hemithorax volume; i.e. if the lung is 9 cm in diameter and the hemithorax 10 cm ($10^3 - 9^3 / 10^3 = 27\%$). This is commonly used method for quantification

of pneumothorax. Rhea and associates have described an alternate method for estimating the percentage of collapse. With their method; the average interpleural distance is calculated. This is the mean of the maximum apical interpleural distance and two measurements of interpleural distances in the mid points of the upper and lower halves of the lung. When this average interpleural distance is obtained, a scale is used to calculate the percentage of the lung that is collapsed.

MANAGEMENT

Treatment of pneumothorax (Chart 2) depends on the size, type of pneumothorax, presence of dyspnea, state of underlying lung, associated complications and recurrence. Various treatment modalities are simple

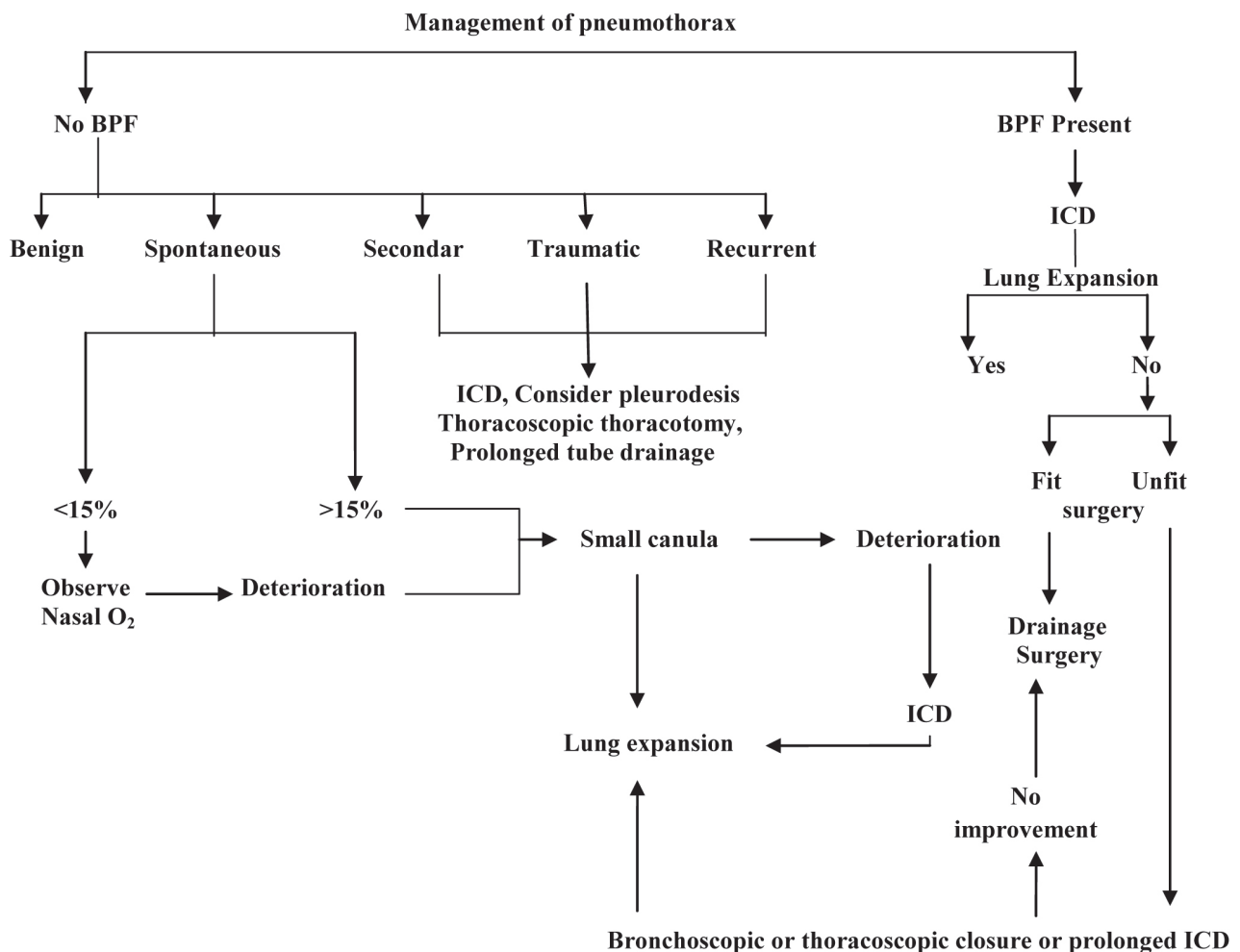


CHART 2. Management of pneumothorax.

needle aspiration, pigtail catheterization or intercostal drainage tubes, thoracoscopy or surgery (Table 3). A benign spontaneous pneumothorax that is small (less than 15%) can be treated with observation alone. The rate of absorption of air is about 1.25% of the total radiographic area per day, so that a 50% pneumothorax may take 4-6 weeks to resolve. Administering large quantities of oxygen can decrease the rate of resolution. As the rate of absorption is very slow, for larger pneumothorax, simple aspiration with small canula or intercostal drainage tube should be used. The role of needle aspiration is limited to emergency treatment of tension pneumothorax to be followed as quickly as possible by intercostal tube drainage (ICD). Large spontaneous pneumothorax, SSP, traumatic pneumothorax, complicated and recurrent pneumothorax is drained by intercostal tube drainage. Precautions should be taken so that there is gradual withdrawal of air especially in longstanding larger pneumothoraces, to avoid re-perfusion pulmonary edema. Re-expansion pulmonary edema is due to increased permeability of the pulmonary vasculature which occurs following thoracocentesis or chest tube placement. For drainage of pneumothorax, ICD is usually inserted between the 4th and 7th intercostal spaces and between the mid and anterior axillary lines (The "Safe Triangle").²² The tip of the tube should be directed upwards. It is a fallacy that drain must be put in a basal position to drain fluid and apical position to drain air. The anterior approach in the second interspace transfixes two major accessory respiratory muscles- the pectoralis major and minor. In case an apical drain is required for an apical loculation of air, the true apical approach above the scapula into the first interspace posteriorly should be preferred. BTS and ACCP have both published guidelines for the treatment of PSP; however they give contradictory recommendations for first-line treatment. The ACCP¹⁷ advises that simple aspiration is rarely appropriate in the treatment of PSP, while the BTS recommend simple aspiration as the first-line treatment

in all PSP requiring intervention. A recent Cochrane report in 2007 systematically reviewed all published randomised control trials that compared simple aspiration versus intercostal tube drainage for spontaneous pneumothorax in adults.²³ It concluded that there was no difference in the immediate success rate of the procedure, early failure rate, or one year success rate between the two groups. However, simple aspiration conferred a number of advantages including; lower percentage of patients hospitalised, decreased duration of stay, and the fact it is a relatively simple procedure to perform. There has been extensive debate regarding the optimal size of the intercostal drain. Evidence now suggests that small-bore pleural catheters are as effective as larger bore intercostal drains in the treatment of spontaneous pneumothorax. No significant correlation has been found between drain size and complication rate, recurrence rate, and length of hospital stay. However, small caliber catheters may not be suitable in the presence of pleural fluid (where they could block) or a large or persistent air leak (owing to inadequate re-expansion). ICD can be connected to a Heimlich valve,²⁴ a chest drainage bag or an underwater seal drainage bottle (Figure 6). Aurosac, used for

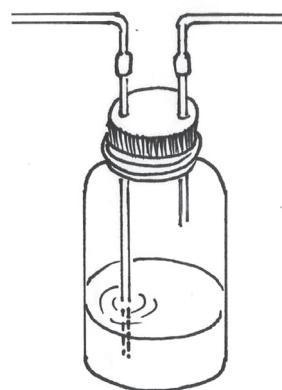

FIGURE 6. Intercostal Drainage with underwater seal.

TABLE 3. Treatment modalities and approach in management of pneumothorax

	Primary	Secondary	Iatrogenic	Traumatic
Observation	<20%	-	<30%	-
Tube thoracostomy	>20%	All	>60%	All
Small tube with one-way valve	-	-	20-60%	-
Pleurodesis	Recurrence × 3	Recurrence × 2-3 Persisting (2 weeks)	-	-
Surgical exploration and repair	-	-	Persisting	Persisting

drainage of urine is easily available and can be used as a pneumosac^{25,26} (Figure 7). They are effective and have the advantage of being less bulky, cheap and allow early mobility. Drains are removed after the lung has expanded fully and does not collapse on clamping and fluid drainage if any is less than 50cc of serous fluid in 24 hours. Patients with bronchopleural fistula needs prolonged drainage. In postoperative leaks, BPFs with small to moderate air leak requiring prolonged drainage or after accidental slipping or removal of ICDs, where pleuro- cutaneous fistula is formed; stoma bags with non-return valves can be used for drainage²⁷ (Figure 8). It helps in reducing duration of hospital stay and chance of infection. The role of Asherman chest seals, sterile occlusive dressing for treating open pneumothorax and preventing tension pneumothorax in chest injuries from gun shots, stab wounds and other penetrating chest trauma is studied.²⁸ This has a same principle as Helmlich valve except there is no intrathoracic component to this device and is just adherent to the chest wall. This could be successfully used in the management of a complicated post- operative leak. Drainable stoma bags also offer a non-return valve mechanism, do not have an intra-thoracic component and are just adherent to the chest wall. For selected patients with persistent air leak not amenable to surgical intervention, identification of air leak site with ventilation scintigraphy followed by



FIGURE 7. Urosac as a drainage bag (pneumosac).

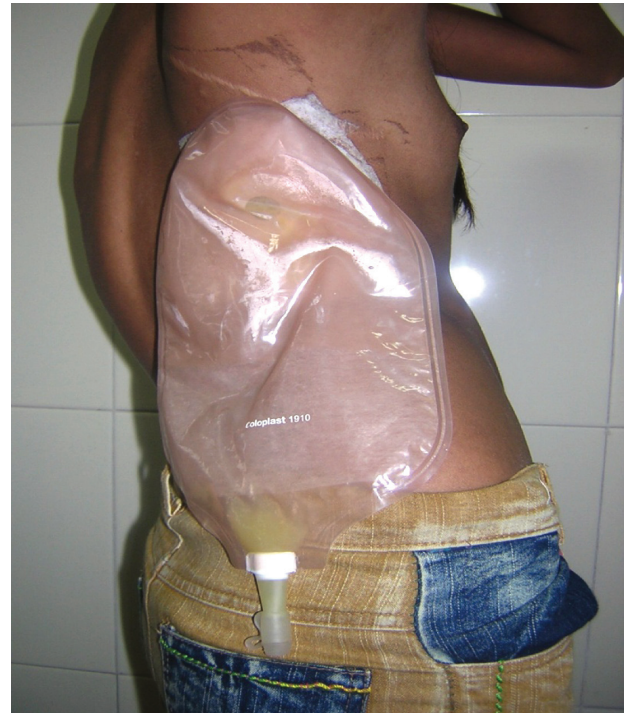

FIGURE 8. Stoma bag with non-return valve used for drainage of pneumothorax.

targeted radiotherapy can be considered. This seals the leak via radiation induced fibrosis.²⁹

Associated BPF is essentially treated by tube drainage; closure of the BPF being the long term goal. Surgical therapy in the form of decortications and closure of BPF with a transposed muscle flap, the pericardial fat pad, or an omental pedicle flap, lobectomy, pleura pneumonectomy or the thoracoplasty are performed depending on patient's condition and the surgeon's skills. Bronchoscopic closure of smaller BPFs with tissue glue, fibrin glue, gel foam, lead plugs, balloon catheter or autologous blood patch can be attempted. The appropriate time for surgery is not known, and it is possible that lung expansion may occur after several weeks of tube drainage. Hence prolonged tube drainage is an alternative approach in selected cases. Patients with BPF requiring ventilator support should be put on high frequency jet ventilators to decrease flow through bronchopleural fistula.

ROLE OF PLEURODESIS

The aim of pleurodesis is to achieve symphysis between visceral and parietal pleural layers, in order to prevent accumulation of air in the pleural space in cases

of recurrent pneumothorax or in patients with persistent air leaks following chest tube drainage. The complete removal of air from the pleural space is needed to keep the visceral and parietal pleural layers in close contact. In a prospective randomized study Almind et al³⁰ compared the recurrence of pneumothorax using drainage alone and drainage plus tetracycline or talc and found a rate of 36%, 13% and 8% respectively, after average follow up of 4.6 years. Alfageme et al³¹ had 9% recurrence with tetracycline pleurodesis as compared to 35% in patients with drainage alone. Since 1935 more than 30 agents have been proposed as sclerosants to induce pleurodesis. In a study by Gyorik et al³² the long-term success rate in preventing pneumothorax recurrence after a successful thorascopic talc pleurodesis was 95% at a median follow-up of 10 years. Commonly used agents for pleurodesis are; tetracycline, talc, doxycycline, minocycline, bleomycin, fibrin glue, autologous blood, povidone iodine, quinacrine. After injecting slurry made of sclerosant with xylocaine, ICD needs to be clamped for one hour and then released for allowing drainage of fluid formed due to inflammatory reaction. Once fluid quantity reduces to less than 50ml of serous fluid, ICD can be removed.

ROLE OF THORACOSCOPY

Thoracoscopy allows simple observation and talc poudrage, Video assisted thoracoscopy (VATS) permits procedures like mechanical pleurodesis, pleurectomy and bullectomy. The accepted surgical indications for pneumothorax include persistent air leak, recurrence, radiologically demonstrated huge bulla, spontaneous hemo-pneumothorax, incomplete expansion of the lung, tension pneumothorax, bilateral involvement and SP in a high-risk occupation such as pilot or scuba divers.³³ A recent consensus from the American College of Chest Physicians recommended the observation of air leaks for 4 days prior to surgical intervention.¹⁷ Patients in good clinical condition, patients with prolonged air leak longer than 5 days due to inadequate lung expansion, and patients with bullae on chest computed tomography are benefited by VATS procedures.³⁴ VATS allows stapling of blebs and small bullae through the use of an endostapler, laser ablation, or electrocoagulation. Repeated talc pleurodesis would make subsequent video-assisted thorascopic surgery to succeed in controlling a persistent air leak due to likely formation of patchy adhesions. Pleurodesis can be done chemically with talc in sufflations or me-

chanically with pleural abrasion or partial pleurectomy. Fluorescence-enhanced autofluorescence thoracoscopy is a new technique; which identify lesions not visible at routine thoracoscopy.

REFERENCES

1. MacDuff A, Arnold A, Harvey J. Management of spontaneous pneumothorax: British Thoracic Society Pleural Disease Guideline 2010; 65(Suppl 2):ii18-ii31.
2. Sahn SA, Heffner JE. Spontaneous pneumothorax. *N Engl J Med* 2000; 342:868-74.
3. Baumann MH. Non-Spontaneous Pneumothorax. In: Light RW, Lee YCG (eds). *Textbook of Pleural Diseases*. Arnold, London, 2003; 464-74.
4. Muramatsu T, Nishii T, Takeshita S, Ishimoto S, Morooka H, Shiono M. Preventing recurrence of spontaneous pneumothorax after thorascopic surgery: a review of recent results. *Surg Today* 2010; 40:696-9.
5. Light RW. Management of spontaneous pneumothorax. *Am Rev Respir Dis* 1993; 148:245-8.
6. Light RW. *Pleural Diseases*, 4th ed, Lippincott, Williams and Wilkins, Philadelphia, PA, 2001.
7. Noppen M, Baumann MH. Pathogenesis and treatment of primary spontaneous pneumothorax: an overview. *Respiration* 2003; 70:431-8.
8. Guo Y, Xie C, Rodriguez RM, Light RW. Factors related to recurrence of spontaneous pneumothorax. *Respirology* 2005; 10:378.
9. Sahn SA, Heffner JE. Spontaneous pneumothorax. *N Engl J Med* 2000; 342:868-74.
10. Waseem M, Jones J, Brutus S, Munyak J, Kapoor R, Gernsheimer J. Giant bulla mimicking pneumothorax. *J Emerg Med* 2005; 29:155-8.
11. Light RW. Pneumothorax. In: Murray JF, Nadel JA, eds. *Textbook of Respiratory Medicine*. Philadelphia, WB Saunders, 1988; pp. 1745-59.
12. DeLassence A, Timsit JF, Tafflet M, et al. Pneumothorax in the intensive care unit: Incidence, risk factors, and outcome. *Anesthesiology* 2006; 104:5-13.
13. Light RW. *Pleural Diseases*. 5th ed. Baltimore, Lippincott, Williams & Wilkins, 2007.
14. Saji H, Nakamura H, Tsuchida T, et al. The incidence and the risk of pneumothorax and chest tube placement after percutaneous CT-guided lung biopsy: The angle of the needle trajectory is a novel predictor. *Chest* 2002; 121:1521-6.
15. Singh N, Agarwal R. Bronchopleural fistula or alveolopleural fistula? Not just semantics. *Chest* 2006; 130:1948.
16. Noppen M, Alexander P, Driesen P, Slabbynck H, Verstraete A. Quantification of the size of primary spontaneous pneumothorax: accuracy of the Lightindex. *Respiration* 2001; 68:396-9.
17. Baumann MH, Strange C, Heffner JE, et al. AACP Pneumothorax Consensus Group. Management of spontaneous pneumothorax: an American College of Chest Physicians Delphi consensus statement. *Chest* 2001; 119:590-602.

18. Simon BC, Paolinetti L. Two cases where bedside ultrasound was able to distinguish pulmonary bleb from pneumothorax. *J Emerg Med* 2005;29:201-5.
19. Hoi K, Turchin B, Kelly AM. How accurate is the light index for estimating pneumothorax size? *Austral Radiol* 2007;51:196-8.
20. Phillips GD, Trotman-Dickensen B, Hodson ME, Geddes DM. Role of CT in the management of pneumothorax in patients with complex cystic lung disease. *Chest* 1997;112:275-8.
21. Mark JBD, McDougall IR. Diagnosis and localization of broncho pulmonary air leaks using ventilation scintigraphy. *Chest* 1997; 111:286-9.
22. Westeby S, Brayley N. Thoracic trauma (ABC of trauma). *Br Med J* 1990; 300:1639-94.
23. Wakai A, O'Sullivan R, McCabe G. Simple aspiration versus intercostal tube drainage for primary spontaneous pneumothorax in adults. *Cochrane Database Syst Rev* 2007; (1):CD004479.
24. Helmlich HJ. Helmlich valve for chest drainage. *Med Instrum* 1983; 17:29-31.
25. Joshi JM. Intercostal tube drainage of pleura: urosac as chest drainage bag. *J Assoc Physicians India* 1996; 44:381-2.
26. Sharma TN, Agnihotri SP, Jain NK, Madan A. Spontaneous pneumothorax: use of urosac as pneumosac. *Ind J Tub* 1987; 34:194-6.
27. Joshi JM. Ambulatory Chest Drainage. *Indian J Chest Dis Allied Sci* 2009; 51:225-31.
28. Rathinam S, Steyn RS. Management of complicated postoperative air-leak- a new indication for the Asherman chest seal. *Interactive Cardiovascular and Thoracic Surgery* 2007; 6:691-4.
29. Ong YE, Sheth A, Simmonds NJ, et al. Radiotherapy: a novel treatment for pneumothorax. *Eur Respir J* 2006;27:427-9.
30. Almind M, Lange P, Viskum K. Spontaneous pneumothorax: comparison of simple drainage, talc pleurodesis, and tetracycline pleurodesis. *Thorax* 1989;44:627-30.
31. Alfageme I, Moreno L, Huertas C, Vargas A, HrrnandezJ, Beiztegui A. Spontaneous pneumothorax: long term results with tetracycline pleurodesis. *Chest* 1994; 106:347-50.
32. Györik S, Erni S, Studler U, Hodek-Wuerz R, Tamm M, Chhajed PN. Long-term follow-up of thoracoscopic talc pleurodesis for primary spontaneous pneumothorax. *Eur Respir J* 2007; 29:757-60.
33. Yim APC, Ng CSH. Thoracoscopic management of spontaneous pneumothorax. *Curr Opin Pulm Med* 2001;7:210-4.
34. Kim SJ, Lee HS, Kim HS, et al. Outcome of Video-assisted Thoracoscopic Surgery for Spontaneous Secondary Pneumothorax. *Korean J Thorac Cardiovasc Surg* 2011; 44:225-8.