

# Miliary tuberculosis with central nervous system involvement in immunosufficient male

**Evangelia Chondrou,**  
**Dimitrios Theofilos,**  
**Charalampos Marketos,**  
**Danai Bisirtzoglou,**  
**Athanasios Zetos,**  
**Georgios Politis**

Pneumology Department, "Saint Savvas"  
Anticancer Hospital, Athens, Greece

A 37 years-old male, with free previous medical history, was presented with low grade fever since last month, photosensitivity and slothfulness.

A chest X-ray showed a diffuse bilateral nodular pattern.

The computed tomography of the chest revealed multiple scattered nodules of 1-3 mm in diameter, expanding in all pulmonary lobes.

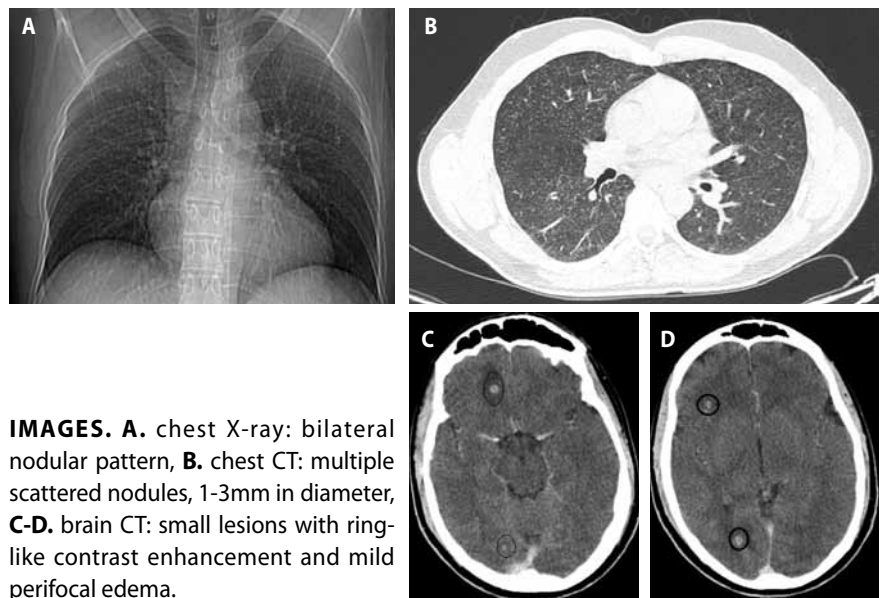
The patient underwent bronchoscopy and transbronchial biopsies were taken the histopathological examination of which confirmed epithelioid granulomas with central necrosis, compatible with tuberculomas.

Moreover, Ziehl-Nielsen staining and  $\beta$ -Koch culture of sputum and washing samples were positive, while Mantoux skin test was negative.

Ophthalmological examination detected an oval yellowish lesion of the right oculus choroidal, resembling tubercle.

In addition, a brain computed tomography demonstrated multiple small lesions with ring-like contrast enhancement and mild perifocal edema in both cerebral hemispheres and posterior fossa, consistent with tuberculosis granulomas.

A quadruple anti-tuberculosis treatment was administered and the patient showed gradually clinical and imaginary improvement on both, lung and brain.



**IMAGES.** **A.** chest X-ray: bilateral nodular pattern, **B.** chest CT: multiple scattered nodules, 1-3mm in diameter, **C-D.** brain CT: small lesions with ring-like contrast enhancement and mild perifocal edema.

## Αλληλογραφία

Ευαγγελία Χονδρού MD, MSc, Πνευμονολόγος,  
Πνευμονολογική κλινική ΓΑΟΝΑ «Ο Άγιος Σάββας»,  
Λεωφ. Αλεξάνδρας 171, ΤΚ 11522 Αθήνα,  
E-mail: pneymoagsavvas@gmail.com