

# Three cases of infection with pulmonary *Mycobacterium Avium* complex with resistance to macrolides secondary to prolonged prior use for bronchiectasis

Katerina Manika<sup>1</sup>,  
Apostolos Papavasileiou<sup>2</sup>,  
Stamatoula Tsirikas<sup>3</sup>,  
Myrto Yannouloupoulou-Remoundou<sup>3</sup>,  
Konstantinos Konstantinou<sup>4</sup>

<sup>1</sup>Pulmonologist, Lecturer, Aristotle University of Thessaloniki

<sup>2</sup>Pulmonologist, Director, Department of Tuberculosis, Athens Chest Hospital "Sotiria"

<sup>3</sup>Pulmonologist, Tuberculosis Department, Athens Chest Hospital "Sotiria"

<sup>4</sup>Pulmonologist, Head, Tuberculosis Department, Athens Chest Hospital "Sotiria"

#### Key words:

- Non tuberculous mycobacteria,
- *Mycobacterium avium* complex,
- bronchiectasis,
- macrolides

#### Correspondence:

Apostolos Papavasileiou  
Department of Tuberculosis, Athens Chest Hospital "Sotiria"  
152 Mesogeion Ave, Athens 11527, Greece  
Tel.: +30 2107763698, Fax: +30 2107791539  
E-mail: apostolospapavasiliou@yahoo.gr

**SUMMARY.** The activity of atypical or non tuberculous mycobacteria (NTM) as pulmonary pathogens has been recognized even in immunocompetent individuals. The *Mycobacterium avium* complex (MAC) is the commonest of the 130 NTMs and comprises two species, *M. avium* and *M. intracellulare*. For the treatment of pulmonary MAC infection combination of a macrolide (azithromycin or clarithromycin) with rifampicin and ethambutol is required. An aminoglycoside (streptomycin or amikacin) should be added in cavitation or severe disease. The treatment is long and expensive, of uncertain efficacy and with serious adverse effects. One quarter of patients either fail to become culture negative or relapse despite treatment. In addition, only 52% of appropriately treated patients show clinical improvement. Resistance to macrolides is a significant negative prognostic factor. As in the case of antituberculosis drugs, the main mechanism of resistance development is prior exposure to monotherapy. Three cases are presented of MAC pulmonary infection with resistance to macrolides, which probably developed secondary to prolonged use for the treatment of exacerbations or maintenance therapy of bronchiectasis. Because of the increasing prevalence of NTM infection, the presence of nodules and bronchiectasis in a patient with pulmonary symptoms should raise the suspicion of NTM disease. The administration of macrolides without sufficient evidence poses the danger of development of resistance in the case of undiagnosed NTM disease, and testing for acid-fast bacilli is imperative before initiation of treatment of bronchiectasis with macrolides. *Pneumon* 2013, 26(2):190-195.

## INTRODUCTION

Atypical or non tuberculous mycobacteria (NTM) have attracted in-

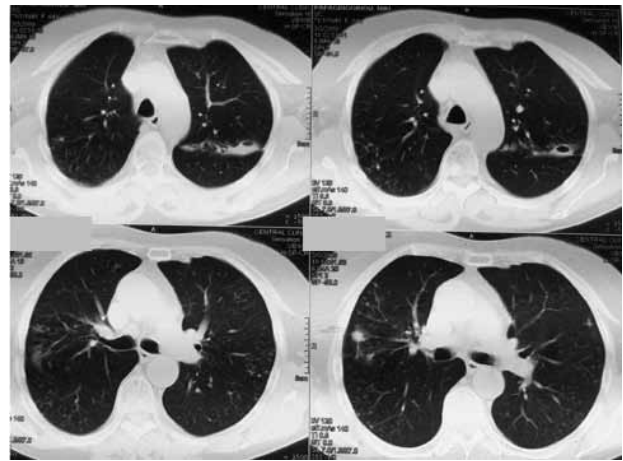
creasing attention internationally as their activity as pulmonary pathogens has been recognized, even in non-immunocompromised individuals<sup>(1,2)</sup>. The most common presentation of NTM infection is pulmonary disease which is radiologically characterized by nodules, bronchiectasis and cavities which have the same morphology as those of tuberculous cavitation<sup>(1)</sup>. The *Mycobacterium avium* complex (MAC) is the commonest of the 130 NTMs and comprises two species, *M. avium* and *M. intracellulare*<sup>(1-3)</sup>. As these two species cannot be differentiated on the basis of physical and biochemical properties, currently the treatment is the same for both<sup>(1)</sup>.

Macrolides such as clarithromycin and azithromycin are the cornerstone of treatment of NTM infection<sup>(1,4,5)</sup>. Three cases are presented here of MAC pulmonary infection with resistance to macrolides, most likely secondary to their prolonged use for the treatment of exacerbations or maintenance therapy of bronchiectasis.

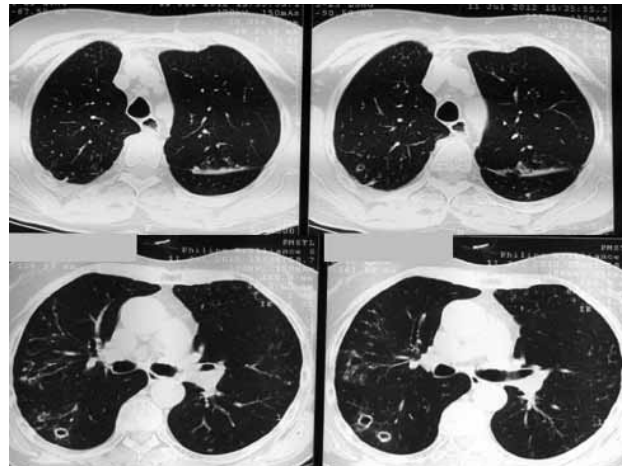
## CASE 1

A 68 year-old woman presented with a 6 year history of productive cough, haemoptysis and breathlessness on exertion. *M. intracellulare* was isolated from her bronchial secretions. The patient had received corticosteroids over the 2007-2009 period on the grounds of a presumptive diagnosis of cryptogenic organising pneumonia (COP), but with no improvement of her symptoms. In 2009 chest computed tomography (CT) revealed a cavity of the left upper lobe, consolidation, bronchiectasis and bilateral pulmonary nodules (Figure 1). As there was generalized deterioration of the radiological picture the diagnosis of COP questioned and the patient underwent bronchoscopic examination. *M. intracellulare* was cultured from the bronchoalveolar lavage (BAL), but at the time this was considered to be a non pathogenic incidental finding and the patient was treated with macrolides twice weekly and bronchodilators, but with no improvement in her symptoms. Chest CT in 2012 revealed resolution of the cavity of the left upper lobe, but a new cavitation in the right upper lobe, consolidation and nodules (Figure 2).

There were no comorbid conditions and the patient's general health status was good, but the symptoms of productive cough and breathlessness on exertion persisted. The results on haematological, biochemical and immunological testing were unremarkable. On the basis of the clinical, radiological and bronchoscopic picture the diagnosis of pulmonary mycobacterial infection with *M.*



**FIGURE 1.** Case 1. 68 year-old female with bronchiectasis and infection with *Mycobacterium avium* complex (MAC): Chest CT 3 years before diagnosis showing cavity of the left upper lobe and multiple bilateral pulmonary nodules.



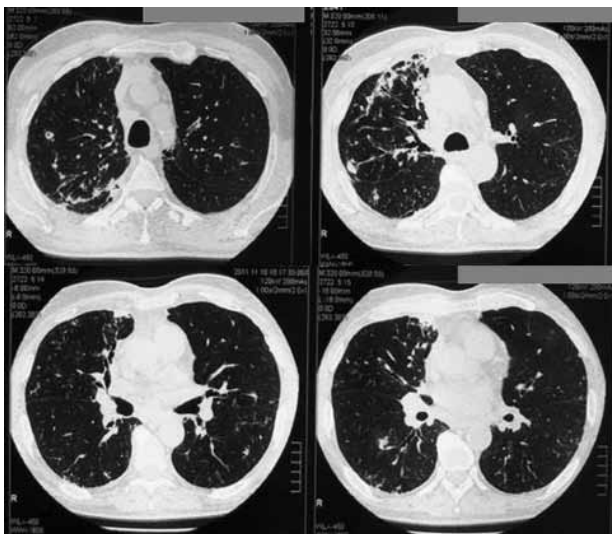
**FIGURE 2.** Case 1. 68 year-old female with bronchiectasis and infection with *Mycobacterium avium* complex (MAC): Chest CT at diagnosis showing resolution of the cavity of the left upper lobe, but new cavitation in the right upper lobe, consolidation and nodules.

*intracellulare* was and combined treatment was started with rifampicin, ethambutol, amikacin, moxifloxacin and isoniazid. The *M. intracellulare* strain was resistant to macrolides, attributed to their use as maintenance therapy for bronchiectasis. Two months later the patient showed significant clinical improvement with gradual resolution of symptoms, weight gain and a fall in the erythrocyte sedimentation rate (ESR), and had become also culture negative.

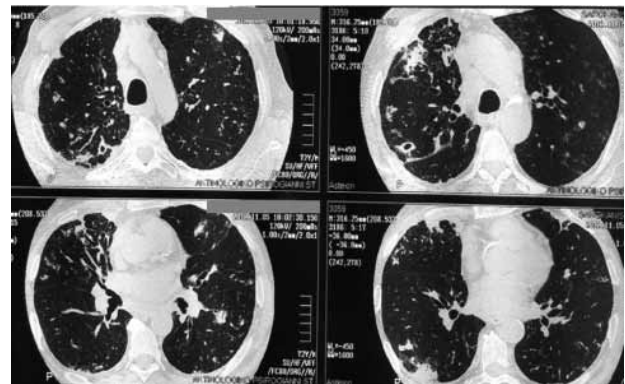
## CASE 2

A 63 year-old male patient with a history of coronary disease and chronic obstructive pulmonary disease (COPD), presented with a 3 year history of productive cough. In 2010 he had been admitted to hospital for investigation of haemoptysis and had received antituberculosis (TB) treatment on the basis of clinical and radiological findings, but with no bacteriological confirmation. There had been no improvement of symptoms during the treatment period and chest CT in 2011 showed subpleural ground glass shadowing and bronchiectasis predominantly in the right upper lobe (Figure 3). Over the preceding 3 years this patient had received repeated courses of macrolides for the treatment of presumed exacerbations of bronchiectasis, which resulted in temporary improvement of his cough. Pulmonary function tests were within normal range.

Chest CT on admission showed radiological progression with the ground glass shadowing now presenting as nodules (Figure 4). Baseline blood tests were unremarkable apart from elevated ESR (48mm/h). Two sputum cultures grew *M. avium*, resistant to macrolides and the patient was started on combined treatment with rifamputin, ethambutol, isoniazid, moxifloxacin and amikacin, which resulted in significant clinical improvement within 2 months.



**FIGURE 3.** Case 2. 63 year-old male with bronchiectasis and infection with *Mycobacterium avium* complex (MAC): Chest CT one year before diagnosis showing bronchiectasis and bilateral pulmonary nodules.

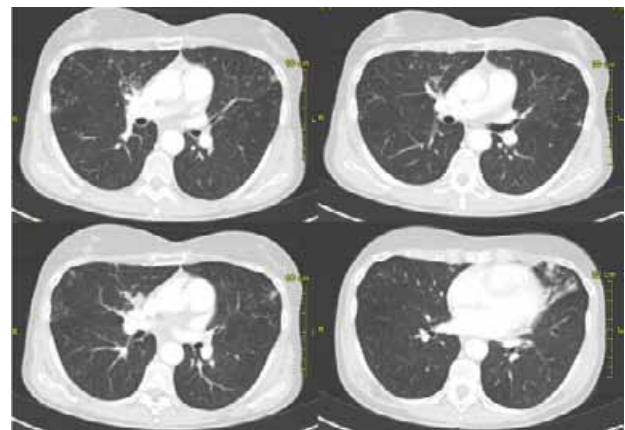


**FIGURE 4.** Case 2. 63 year-old male with bronchiectasis and infection with *Mycobacterium avium* complex (MAC): Chest CT at diagnosis showing consolidation, bronchiectasis, cavitation and nodules bilaterally.

## CASE 3

A 56 year-old female patient presented with a 3 year history of productive cough, occasional blood stained sputum, low grade fever and shortness of breath. Chest CT in 2009 revealed bronchiectasis in the lingula. Because of sputum cultures positive for *Pseudomonas aeruginosa* had been receiving macrolides twice weekly for the previous two months. Appropriate treatment with antipseudomonal penicillins resulted in only temporary improvement.

Chest CT in 2013 revealed radiological deterioration with bilateral "tree in bud" changes and consolidation (Figure 5). Haematological, biochemical and immunologi-



**FIGURE 5.** Case 3. 53 year-old female with bronchiectasis and infection with *Mycobacterium avium* complex (MAC): Chest CT at diagnosis showing, bronchiectasis and multiple nodules bilaterally.

cal testing showed no abnormalities. BAL fluid culture grew *M. intracellulare*, resistant to macrolides. Combined treatment consisting of rifamputin, ethambutol, isoniazid, moxifloxacin and amikacin was prescribed.

## DISCUSSION

Apart from their undisputed role in the treatment of lower respiratory tract infections, macrolides have, over the last 30 years, have also proved to have significant anti-inflammatory and immunomodulatory properties<sup>(6)</sup>. These properties have been demonstrated by *in vitro* and experimental observation<sup>(7)</sup>, and have also been observed in clinical practice<sup>(6,8,9)</sup>, in the treatment of diffuse panbronchitis<sup>(8)</sup> and cystic fibrosis (CF)<sup>(8,10)</sup>. In CF their action includes the breakdown of the *P. aeruginosa* biofilm and attenuation of its virulence factors<sup>(6,11)</sup>. It should be noted that these anti-inflammatory properties are observed at concentrations lower than those given for treatment of MIC. On the basis that improvement of pulmonary function and reduction of exacerbations have been observed in prospective trials, the formal guidelines now support the use of low dose azithromycin for patients with CF colonised by *P. aeruginosa*<sup>(12)</sup>.

The use of macrolides in non-CF bronchiectasis is based on extrapolation from the above studies, but does not have adequate trial support. According to recent studies the use of macrolides, principally azithromycin, in subtherapeutic doses reduces exacerbations and bacterial load and improves pulmonary function in patients with bronchiectasis<sup>(13-15)</sup>, but these were studies of small numbers of patients and the heterogeneity of their design does not permit safe cumulative result deduction. This is the reason the recent guidelines of the British Thoracic Society (BTS) Bronchiectasis non-CF Guideline Group concluded that in order for the role of macrolides in non-CF bronchiectasis to be defined, larger randomised controlled trials need to be conducted<sup>(16)</sup>.

The principal disadvantage of long term administration of macrolides is the development of resistant microbial strains<sup>(11,17)</sup>. This is already apparent in Greece where the macrolide resistance of *Streptococcus pneumoniae* exceeds 25% and essentially precludes treatment of community acquired pneumonia (CAP) with macrolide monotherapy, in contrast with many other places in the world which report much lower percentages of macrolide resistance<sup>(18,19)</sup>. In the same way, the long term administration of macrolides for the treatment of frequent exacerbations

of bronchiectasis enhances the development of resistant strains of NTM<sup>(11,17)</sup>.

Bronchiectasis and NTM infection, especially MAC, often co-exist and sometimes it is impossible to discern whether the NTM is the cause of the bronchiectasis or the reverse<sup>(1,20)</sup>. Patients with NTM infection often have a background of chronic respiratory disease such as COPD, old TB, lung cancer or bronchiectasis<sup>(1,2)</sup>. A recent study showed that patients who had actual disease caused by NTM, as opposed to colonisation only, were more likely to have bronchiectasis<sup>(2)</sup> and the extent of the bronchiectasis was related to the persistence of positive cultures<sup>(20)</sup>.

The co-existence of other respiratory conditions in patients with NTM makes the diagnosis of NTM infection more difficult and time consuming. The cases reported here presented with typical symptoms and findings, but in all the patients the final diagnosis of MAC pulmonary infection was made several years after the onset of their symptoms. This is not unusual, since 8% of patients considered to have Tb have been found to be suffering from mycobacteriosis due to NTM<sup>(21)</sup>. A possible explanation may be the low level of suspicion, particularly in countries where Tb is significantly more prevalent. In that setting, the decision to treat Tb based on clinical and radiographic findings, without microbiological confirmation, presents the danger of missing the diagnosis of NTM infection, as in case 2.

The delay in diagnosis and the administration of macrolides in spite of MAC presence in the BAL in case 1 and without testing for NTM in the other two cases may in practice reflect the general view that NTM infection is limited to immunocompromised patients. Current documentation, however, indicates that only 25% of patients with confirmed NTM infection are under immunosuppressive treatment<sup>(2)</sup>. The prevalence of infection due to NTM is rising worldwide<sup>(2,4,22)</sup> and in some areas is even higher than that of Tb<sup>(2)</sup>. It is therefore evident that the sputum of patients with bronchiectasis should be tested for acid-fast bacilli (AFB) both with Ziehl-Neelsen stain and molecularly (AMTD-Genprobe). The molecular method is indicated even for stain-negative samples. In the case of a positive stain but negative molecular test, NTM should be suspected if clinical and radiological findings are consistent with this diagnosis. A second negative molecular test for Tb renders the diagnosis of NTM infection highly probable.

Pulmonary NTM infection is more common in adults of middle or older age and particularly women<sup>(1)</sup>. Since NTM are ubiquitous, their presence in one sputum sample

does not confirm the diagnosis. According to the American Thoracic Society (ATS), suggested criteria for diagnosing NTM lung disease consist of: 1) pulmonary symptoms, 2) the presence of nodules, cavities or bronchiectasis, and 3) positive culture from at least two expectorated sputum samples or one bronchial wash or lavage<sup>(1)</sup>. The NTM most commonly responsible for pulmonary disease is MAC<sup>(1-3)</sup>. The treatment of MAC infection consists of combination therapy with a macrolide (azithromycin or clarithromycin), rifampicin and ethambutol. An aminoglycoside (streptomycin or amikacin) should be added in the case of cavitational or severe disease. The introduction of the newer macrolides in the treatment regime of pulmonary MAC disease is a major therapeutic advance. In addition, macrolides are the only drug in the treatment of MAC disease for which *in vitro* susceptibility corresponds with clinical efficacy<sup>(1,23)</sup>.

Patients with MAC pulmonary disease should be treated for a period of 12 months after sputum cultures have become negative<sup>(1,24)</sup>, but the treatment is expensive, has significant adverse reactions and is often ineffective<sup>(2,25)</sup>. In contrast to Tb where cure is achieved in the vast majority of cases, because of the susceptibility of most strains, the outcome of pulmonary MAC disease is less certain, similar to the case of multi drug-resistant Tb. According to studies conducted in immunocompetent adults, one quarter of patients fail to become culture negative or relapse despite treatment<sup>(26,27)</sup>. Mortality even for those receiving treatment is as high as 22%<sup>(28)</sup>, but this percentage reflects all-cause mortality and patients with NTM infection are usually old and have multiple comorbidities. Regardless of this, the poor outcome of MAC infection is unquestionable since 53% of patients with pulmonary MAC disease and bronchiectasis deteriorate in a period of 10 years<sup>(24)</sup> and only 52% of appropriately treated patients show clinical improvement<sup>(23)</sup>.

Based on the evidence reviewed above, treating pulmonary MAC infection presents significant challenges to the clinician, particularly when the organism is resistant to macrolides. In a study of 51 HIV negative patients infected with resistant MAC, negative culture conversion was achieved in 79% of those who treated with injectable agents for a period of at least 6 months and underwent surgery, but only 5% of those undergoing only one form of treatment<sup>(29)</sup>. The significance of resistance to macrolides has been documented repeatedly<sup>(4,5)</sup> and it is considered to be a major negative prognostic factor<sup>(24)</sup>. It is clear that the appropriate treatment for macrolide-resistant MAC has not been effectively determined<sup>(1)</sup>.

As in the case of antituberculous drugs, the main mechanism of resistance development is exposure to monotherapy. It has been known for 20 years that patients with AIDS receiving macrolides as prophylaxis for disseminated MAC infection are in danger of developing resistance<sup>(30)</sup>. Resistance has also been confirmed in HIV negative individuals who were undergoing monotherapy with macrolides for MAC infection, before the ATS guidelines were introduced. After 4 months of monotherapy 20% of patients developed resistance to macrolides<sup>(29)</sup>. These data support the attribution of resistance in the patients presented here to previous macrolide use, either as treatment of exacerbations or for maintenance therapy of bronchiectasis.

In conclusion, it is evident that development of resistance to macrolides in a patient with MAC infection leads to the necessity for a complex therapeutic regimen, with doubtful expectations of compliance and an uncertain outcome. Because of the increasing prevalence of NTM infections, the presence of nodules and bronchiectasis in a patient with pulmonary symptoms should raise the clinical suspicion of NTM disease. In addition, the administration of macrolide monotherapy without sufficient evidence poses the danger of resistance development in the case of undiagnosed NTM disease. For these reasons, testing for AFB bacilli before initiation of macrolides is imperative and this should be considered the appropriate approach in everyday clinical practice.

## REFERENCES

1. Griffith DE, Aksamit T, Brown-Elliott BA et al. An Official ATS/IDSA Statement: Diagnosis, Treatment, and Prevention of Nontuberculous Mycobacterial Diseases. *Am J Respir Crit Care Med* 2007;175: 367-416.
2. Winthrop KL, McNelley E, Kendall B et al. Pulmonary nontuberculous mycobacterial disease prevalence and clinical features: an emerging public health disease. *Am J Respir Crit Care Med* 2010 Oct 1;182(7):977-82.
3. Gitti Z, Mantadakis E, Maraki S, Samonis G. Clinical significance and antibiotic susceptibilities of nontuberculous mycobacteria from patients in Crete, Greece. *Future Microbiol* 2011 Sep;6(9):1099-109.
4. Griffith DE. Therapy of nontuberculous mycobacterial disease. *Curr Opin Infect Dis* 2007;20(2):198-203.
5. Griffith DE, Aksamit TR. Therapy of refractory nontuberculous mycobacterial lung disease. *Curr Opin Infect Dis* 2012;25(2):218-27.
6. Amsden GW. Anti-inflammatory effects of macrolides--an underappreciated benefit in the treatment of community-acquired respiratory tract infections and chronic inflammatory pulmonary conditions? *J Antimicrob Chemother* 2005;55(1):10-21.

7. Manika K, Kioumis I. The clinical significance of *Streptococcus pneumoniae* resistance in community-acquired pneumonia. *Pneumon* 2011, 24(4):379-387.
8. Friedlander AL, Albert RK. Chronic macrolide therapy in inflammatory airways diseases. *Chest* 2010;138(5):1202-12.
9. Kudoh, S. Erythromycin treatment in diffuse panbronchiolitis. *Curr Opin Pulm Med* 1998;4(2):116-21.
10. Bell SC, Senini SL, McCormack JG. Macrolides in cystic fibrosis. *Chron Respir Dis* 2005;2(2):85-98.
11. King P. Is there a role for inhaled corticosteroids and macrolide therapy in bronchiectasis? *Drugs* 2007;67(7):965-74.
12. Flume PA, O'Sullivan BP, Robinson KA et al. Cystic Fibrosis Pulmonary Guidelines. Chronic Medications for Maintenance of Lung Health. *Am J Respir Crit Care Med* 2007;176:957-969.
13. Anwar GA, Bourke SC, Afolabi G, Middleton P, Ward C, Rutherford RM. Effects of long-term low-dose azithromycin in patients with non-CF bronchiectasis. *Respir Med* 2008;102(10):1494-6.
14. Wong C, Jayaram L, Karalus N, et al. Azithromycin for prevention of exacerbations in non-cystic fibrosis bronchiectasis (EMBRACE): a randomised, double-blind, placebo-controlled trial. *Lancet* 2012;380(9842):660-7.
15. Serisier DJ, Martin ML. Long-term, low-dose erythromycin in bronchiectasis subjects with frequent infective exacerbations. *Respir Med* 2011;105(6):946-9.
16. Pasteur MC, Bilton D, Hill AT; British Thoracic Society Bronchiectasis non-CF Guideline Group. British Thoracic Society guideline for non-CF bronchiectasis. *Thorax* 2010;65 Suppl 1:i1-58.
17. Altenburg J, de Graaff CS, van der Werf TS, Boersma WG. Immunomodulatory effects of macrolide antibiotics - part 2: advantages and disadvantages of long-term, low-dose macrolide therapy. *Respiration* 2011;81(1):75-87.
18. Mandell LA, Wunderink RG, Anzueto A; Infectious Diseases Society of America; American Thoracic Society. Infectious Diseases Society of America/American Thoracic Society consensus guidelines on the management of community acquired pneumonia in adults. *Clin Infect Dis* 2007;44(Suppl. 2):S27-72.
19. Consensus Workshop of the Hellenic Society of Infectious Diseases, the Hellenic Society of Chemotherapy and the Hellenic Thoracic Society. Guidelines for the diagnosis and empiric treatment of community acquired pneumonia. In: *Guidelines for the Diagnosis and Empiric Treatment of Infections*, from: Hellenic Center for Diseases Control and Prevention, Scientific Committee of Nosocomial Infections. Editor: Hellenic Society of Infectious Diseases. Athens 2007, pp 33-46.
20. Kuroishi S, Nakamura Y, Hayakawa H, Shirai M, Nakano Y, Yasuda K, Suda T, Nakamura H, Chida K. *Mycobacterium avium* complex disease: prognostic implication of high-resolution computed tomography findings. *Eur Respir J* 2008;32(1):147-52.
21. Maiga M, Siddiqui S, Diallo S, et al. Failure to recognize nontuberculous mycobacteria leads to misdiagnosis of chronic pulmonary tuberculosis. *PLoS One* 2012;7(5):e36902.
22. Zheng C, Fanta CH. Nontuberculous mycobacterial pulmonary infection in the immunocompetent host. *QJM*. 2013 Jan 29. [Epub ahead of print]
23. Kobashi Y, Yoshida K, Miyashita N, Niki Y, Oka M. Relationship between clinical efficacy of treatment of pulmonary *Mycobacterium avium* complex disease and drug-sensitivity testing of *Mycobacterium avium* complex isolates. *J Infect Chemother* 2006;12(4):195-202.
24. Kitada S, Uenami T, Yoshimura K, et al. Long-term radiographic outcome of nodular bronchiectatic *Mycobacterium avium* complex pulmonary disease. *Int J Tuberc Lung Dis* 2012;16(5):660-4.
25. van Ingen J, Boeree MJ, van Soolingen D, Mouton JW. Resistance mechanisms and drug susceptibility testing of nontuberculous mycobacteria. *Drug Resist Updat* 2012;15(3):149-61.
26. Kim EY, Chi SY, Oh IJ, et al. Treatment outcome of combination therapy including clarithromycin for *Mycobacterium avium* complex pulmonary disease. *Korean J Intern Med* 2011;26(1):54-9.
27. The Research Committee of the British Thoracic Society. Pulmonary disease caused by *Mycobacterium avium*-intracellulare in HIV-negative patients: five-year follow-up of patients receiving standardised treatment. *Int J Tuberc Lung Dis* 2002;6(7):628-634.
28. Ito Y, Hirai T, Maekawa K, et al. Predictors of 5-year mortality in pulmonary *Mycobacterium avium*-intracellulare complex disease. *Int J Tuberc Lung Dis* 2012;16(3):408-14. doi: 10.5588/ijtld.11.0148. Epub 2012 Jan 5.
29. Griffith DE, Brown-Elliott BA, Langsjoen B, et al. Clinical and molecular analysis of macrolide resistance in *Mycobacterium avium* complex lung disease. *Am J Respir Crit Care Med* 2006;174(8):928-34. Epub 2006 Jul 20.
30. Craft JC, Notario GF, Grosset JH, Heifets LB. Clarithromycin resistance and susceptibility patterns of *Mycobacterium avium* strains isolated during prophylaxis for disseminated infection in patients with AIDS. *Clin Infect Dis* 1998;27(4):807-12.