

# Virtual CT-bronchoscopy and lung cancer

**Christophoros Kotoulas<sup>1</sup>,**  
**Panagiotis Panagou<sup>2</sup>,**  
**Eleni Patsea<sup>3</sup>,**  
**Charalampos Psaras<sup>2</sup>**

<sup>1</sup>Dept of Cardiothoracic Surgery, «IASO» General Hospital of Athens

<sup>2</sup>Medical Research Center, Lamia

<sup>3</sup>Dept of Pathology, «IASO» General Hospital of Athens

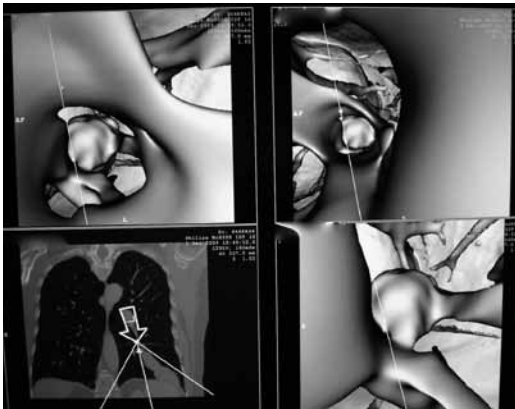
A 70-year-old female presented with a lesion in the left lower pulmonary area in a random examination. She was a heavy smoker and she had a history of hypothyroidism. Computed tomography (CT) scan did not reveal the presence of lymph nodes or other distant metastases. The characters of the lesion were compatible with malignant pathology. Because of dual unsuccessful effort of fibero bronchoscopy, virtual CT-bronchoscope was decided and no other pathology was revealed (Figure 1).

After complete preoperative preparation without contraindications for surgery, she underwent a lower lobectomy and complete lymph node dissection, through a left thoracotomy. After induction in anesthesia the patient underwent fibero bronchoscopy and the findings of virtual CT-bronchoscopy were confirmed.

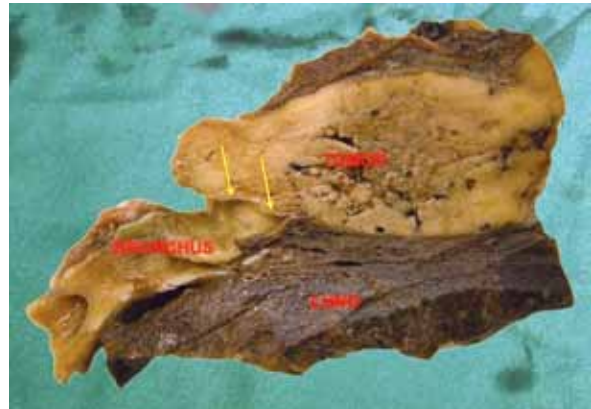
Histological diagnosis showed a squamous-cell tumor with moderate differentiation. The TNM stage was IIa (T2bN0M0) (Figure 2).

She had an uneventful recovery. The patient followed postoperative chemotherapy. The patient is alive and disease-free 26 months after.

Since 1996, when virtual CT-bronchoscopy was first used, there has been a rapid improvement in its software. In recent years it has been combined with other techniques aiming to take biopsies to diagnose lung diseases.



**FIGURE 1.** Virtual CT-bronchoscopy showed the presence of a tumor in the left lower bronchus.



**FIGURE 2.** Formalin-fixed excised lung parenchyma.

### Correspondence to:

Christophoros Kotoulas MD, PhD, FETCS, FCCP  
Kifissias Ave 38, Ampelokipoi, Athens, GR-11526 Greece  
Tel.: +30 210 7782220, Fax: +30 210 7772329  
E-mail: info@kotoulas.com - Website: www.kotoulas.com