

New Guidelines for Idiopathic Pulmonary Fibrosis: The Acute Exacerbation «Affair»

**Konstantinos Kagouridis¹ MD,
Effrosyni D Manali² MD,
Likourgos Kolilekas¹ MD,
Christina Triantafillidou² MD,
Spyros A Papiris¹ MD, FCCP**

¹2nd Pneumology Department, "Attikon"
University Hospital, Athens Medical School,
National and Kapodistrian University of
Athens,

²1st Pneumology Department, "Sotiria"
Chest Diseases Hospital, Athens Medical
School, National and Kapodistrian University
of Athens, Greece

Key words:

- idiopathic pulmonary fibrosis acute exacerbation,
- immunosuppression,
- corticosteroids

Correspondence to:

Spyros A. Papiris,
Professor of Medicine, Head 2nd Pneumology Dept,
"Attikon" University Hospital, 1 Rimini Street,
12462, Haidari, Greece,
Tel.: +302105832361, Fax: +302105326414,
e-mail: papiris@otenet.gr

The new guidelines for diagnosis and management of Idiopathic Pulmonary Fibrosis (IPF) constitute a valuable aid for the clinician because they clarify several "dark" points that have been brought up during the last decade by intense research and an increasing body of evidence in IPF^{1,2}. As such we could mention:

- 1) The ability to diagnose IPF without the need of histologic confirmation when typical clinical and radiological findings in high-resolution computed tomography are present as well as the ability to make the diagnosis of IPF based on a number of combinations of HRCT and surgical lung biopsy patterns in a background of multidisciplinary discussion between pulmonologists, radiologists and pathologists.
- 2) The variety of "natural histories" of IPF: IPF can progress slowly for more than five years or progress rapidly within 2 years and in any time may be complicated by a subacute/acute deterioration of respiratory function without any evident cause, which is defined as IPF acute exacerbation.
- 3) The role that co-morbid conditions such as pulmonary emphysema, pulmonary hypertension, gastroesophageal reflux, obstructive sleep apnea syndrome and obesity could play in the progression of IPF³.
- 4) The realization that all drugs tested up to now have failed. This is considered a very important step forward since it's the first time that the scientific community based on research evidence has decided to abandon the positive recommendation for immunosuppressive/immunomodulatory treatment either with corticosteroids or colchicine alone or with the combination of corticosteroids and azathioprine, cyclosporin A or interferon- γ 1b that have been used for decades in IPF without any proven benefit but with the cost of grave side effects such as drug toxicity and infections. Recommendations have also been negative for endothelin-1 receptor antagonists and anti-TNF factors in IPF⁴.

However, in the new IPF guidelines there is a major discordance between the recommendation for treatment of acute exacerbation of IPF and the one concerning stable IPF. The committee advises the administration of corticosteroids for the exacerbations of IPF based on anecdotal reports of benefit and the high mortality of IPF acute exacerbation although it is clearly stated that there are no controlled trials on which to judge efficacy of such treatment. In stable IPF it is recommended not to use corticosteroids (and

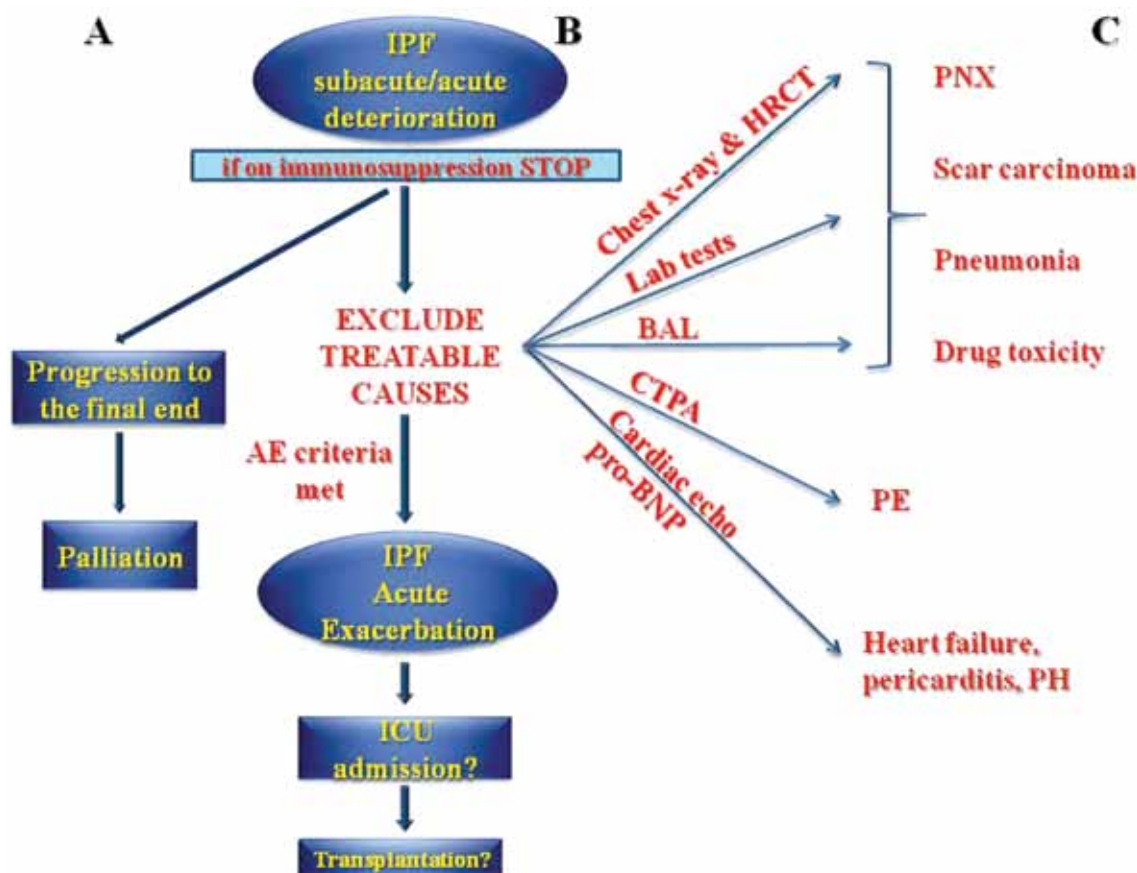


FIGURE 1. Clinical scenarios for the IPF patient presenting in the emergency department with subacute/acute dyspnea. A. Progression to the final end of the disease. B. "Idiopathic" exacerbation of IPF. C. Exacerbation of IPF due to treatable causes. IPF: idiopathic pulmonary fibrosis. AE criteria: Acute Exacerbation criteria of IPF that include: (1) previous or concurrent diagnosis of IPF; (2) unexplained worsening or development of dyspnea within 30 days; (3) high-resolution computed tomography scan showing bilateral ground-glass abnormality and/or consolidation superimposed on a background of reticular or honeycomb pattern compatible with the pattern of IPF - usual interstitial pneumonia (UIP); (4) no evidence of pulmonary infection by endotracheal aspirate or bronchoalveolar lavage; (5) exclusion of alternative causes including left heart failure, pulmonary embolism and identifiable causes of lung injury. Lab (laboratory) tests: C-reactive protein, procalcitonin, N-terminal-pro Brain Natriuretic Peptide (pro-BNP), troponin, complete blood count, D-dimers, erythrocyte sedimentation rate, blood/sputum/bronchoalveolar lavage fluid cultures/polymerase chain reaction for microbes, mycobacteria, atypical pathogens, opportunistic infections, fungi, viruses. BAL: bronchoalveolar lavage. Cardiac echo: cardiac echocardiography, CTPA: computed tomography pulmonary angiography. HRCT: high-resolution computed tomography, ICU: intensive care unit, Lab tests: laboratory tests, PE: pulmonary embolism. PH: pulmonary hypertension, PNX: pneumothorax. With permission from reference 3 (modified).

all other immunosuppressants) in the majority of patients based on the lack of randomized controlled trials as well as on the steroid treatment related morbidity and very low-quality evidence for the potential improvement in pulmonary function. This discordance implies different pathophysiologic mechanisms in stable and in exacerbated IPF which are not however further explained.

IPF acute exacerbation criteria include an unexplained worsening of dyspnea within 1 month, evidence of hy-

poxemia as defined by worsened or severely impaired gas exchange, new radiographic alveolar infiltrates and an absence of an alternative explanation such as infection, pulmonary embolism, pneumothorax or heart failure⁵. Thus the definition of IPF exacerbation defines it as an "idiopathic" exacerbation of an "idiopathic" disease. The best etiological hypothesis for IPF acute exacerbation is that of a clinically "occult" infection that finally develops triggered by a number of undefined patient-related or

environmental factors such as the commonly and unjustified administration of immunosuppressants, that precipitates the usual interstitial pneumonia (UIP) scarred lung to diffuse alveolar damage (DAD) with the development of acute lung injury (ALI)/ acute respiratory distress syndrome (ARDS)⁶.

The clinician that treats an IPF patient presenting in the emergency department with subacute/acute dyspnea should identify if possible the cause of the deterioration⁶. This could be either the progression to the final end of the disease where the architectural distortion of lung parenchyma and the change in the mechanical properties of the lung render spontaneous breathing unbearable, or the coexistence of treatable causes or the acute exacerbation of IPF when all the above scenarios have been excluded (Figure1).

As in ARDS the treatment of IPF exacerbations should consist of excellent supportive care, intense investigation for the possibility of reversible causes and immediate cessation of any immunosuppressive medication⁷. The rapid deterioration of IPF should be considered to be exactly this: an ARDS of known/proven or unknown/unproven (acute exacerbation of IPF) cause upon UIP lung^{8,9}.

Research concerning the natural history and the acute exacerbation of IPF has always been based on IPF patients participating in their vast majority in immunosuppressive treatment protocols. The evaluation and study of IPF patient populations receiving immunosuppressive treatment on the one hand and those being treatment naïve on the other could help to distinguish which of the

IPF complications that are considered part of the natural history of the disease could be partly attributed to the use of off-label immunosuppressive treatment.

REFERENCES

1. Raghu G, Harold R, Collard HR, et al. An Official ATS/ERS/JRS/ALAT Statement: Idiopathic Pulmonary Fibrosis: Evidence-based Guidelines for Diagnosis and Management. *Am J Respir Crit Care Med* 2011;183:788-824.
2. Bouros D. The new ATS/ERS/JRS IPF Guidelines. *Pneumon* 2008;21:117-118.
3. Bouros D. Combined pulmonary fibrosis and emphysema syndrome. *Pneumon* 2009; 22: 126-130.
4. Bouros D, Tzouveleki A. Interferon-gamma for the treatment of idiopathic pulmonary fibrosis. *Pneumon* 2009; 22: 13-17.
5. Collard HR, Moore BB, Flaherty KR, et al; Idiopathic Pulmonary Fibrosis Clinical Research Network Investigators: Acute exacerbations of idiopathic pulmonary fibrosis. *Am J Respir Crit Care Med* 2007, 176:636-643.
6. Papiris SA, Manali ED, Kolilekas L, et al. Idiopathic Pulmonary Fibrosis Acute Exacerbations: Unravelling Ariadne's thread. *Crit Care* 2010;14:246.
7. Papiris SA, Manali ED, Kolilekas L, Triantafyllidou C, Tsangaris I, Kagouridis K. Steroids in Idiopathic Pulmonary Fibrosis acute exacerbation: defenders or killers? *Am J Respir Crit Care Med*. 2011 In press.
8. Wheeler AP, Bernard GR. Acute lung injury and the acute respiratory distress syndrome: a clinical review. *Lancet* 2007, 369:1553-1565.
9. Matthay MA, Zimmerman GA. Acute Lung Injury and the Acute Respiratory Distress Syndrome: four decades of inquiry into pathogenesis and rational management. *Am J Respir Cell Mol Biol* 2005, 33:319-327.