

# A 75 year-old male with a solitary pulmonary mass, pleuritic pain and persistent fever

Zafeiris Sardelis<sup>1</sup>,  
Loukas Thanos<sup>2</sup>,  
Ioannis Vamvakaris<sup>3</sup>,  
Kostantinos Gakis<sup>1</sup>,  
Kostantinos Belentzas<sup>1</sup>,  
Silvia Dumitrou<sup>1</sup>,  
Epaminondas Kosmas<sup>1</sup>

<sup>1</sup>3<sup>rd</sup> Department of Pneumology Medicine,  
<sup>2</sup>CT department,  
<sup>3</sup>Department of Pathology,  
'Sotiria' Hospital for Chest Diseases, Athens

### Key words:

- cutaneous and non-cutaneous melanomas
- primary malignant melanoma of the lung (PMML)
- diagnostic criteria
- surgery
- adjuvant chemotherapy and radiotherapy
- splenic metastases

### SUMMARY.

The lung is an extremely rare primary site for the development of malignant melanoma, in contrast with other tissues where this tumour presents, such as skin, head and neck mucosa, eyes and the gastrointestinal tract. Primary malignant melanoma of the lungs (PMML) is a diagnostic challenge, as clinically and radiologically it cannot be distinguished from the usual primary bronchogenic lung cancer, and its histopathological and immunohistochemical characteristics are little different from those of a lung metastasis from another primary site of malignant melanoma, which is more common. Its diagnosis is based on a number of clinical, radiological and histopathological criteria. In addition, because of its rarity, the knowledge and experience about the prognosis and treatment modalities concerning PMML are inadequate, due to lack of large series. From the little that we know, it appears to be a tumour with poor prognosis, which should be treated by radical surgery, if this is possible, followed by adjuvant chemotherapy and radiotherapy, practically the same as those used for skin melanomas. Metastases to the spleen are an unusual manifestation of malignant melanoma, and may be the cause of continuous high fever. *Pneumon 2011, 24(1):92-97.*

### INTRODUCTION

Melanoma or malignant melanoma is a malignant tumour originating in the melanocytes, cells which are responsible for the production of melanin, a dark pigment, with a significant protective role in the absorption of the ultraviolet (UV) radiation of sunlight. Melanocytes are located predominantly in the skin, and more specifically within the basal layer of the epidermis, at the dermo-epidermal junction.<sup>4</sup> As a consequence, cutaneous melanomas constitute the vast majority (95%) of these malignant tumours.<sup>5</sup> Melanocytes arise from the neural crest of the embryo, and migrate during embryogenesis, not only to the skin, but also to the uvea, meninges and endodermal mucosa.<sup>4</sup> As a result, these tissues can develop the entity of primary non-cutaneous melanoma, which is very rare in comparison

### Correspondence to:

Zafeirios Sardelis  
3<sup>rd</sup> Department of Pneumology Medicine, 'Sotiria'  
Hospital for Chest Diseases,  
Ippokratous 15, Metamorphosi, Athens  
14452  
Greece  
E-mail: [zafsard@yahoo.com](mailto:zafsard@yahoo.com)

with the cutaneous form. Among these non-cutaneous tumours, approximately 80% are located in the eye, representing the most usual ophthalmic cancer in adult Caucasians, while the remaining 20% (1% of all melanomas), develop in the mucous membranes of the head and neck, gastrointestinal (GI) tract, respiratory tract, female reproductive system, and sinuses, and are defined as mucosal melanomas.<sup>5</sup> The most common mucosal sites are the head and neck (55% of all mucosal melanomas), and anus (24%),<sup>6,7</sup> while vulvar melanoma is the second most common cancer of the vulva.<sup>5</sup>

Compared with cutaneous melanomas, the non-cutaneous forms, although they share the same cell origin, differ in their molecular biology, epidemiology (they appear in older ages), aetiology (they do not have a clear relationship with UV radiation or with moles), and prognosis (which is usually worse, due to late diagnosis and their aggressive biological behaviour, due to the rich vascular and lymphatic supply of the mucosal sites).<sup>6,8</sup> These characteristics create a challenge for future research on the treatment of choice, as the current knowledge and experience is poor, because of the lack of large series, in contrast to the extensive documentation on cutaneous melanoma.

Primary malignant melanoma of the lung (PMML), represents an extremely rare sub-category of primary non-cutaneous melanomas, to which the case of the patient presented here belongs.

## CASE REPORT

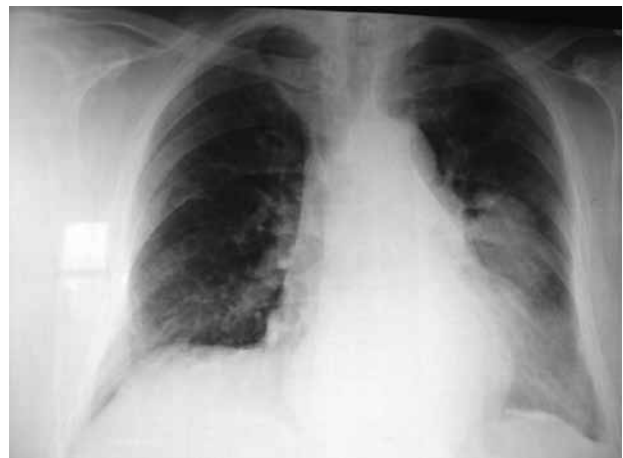A 75 year-old male was admitted as an emergency, reporting a one month history of severe pain at the front of the left hemithorax, fever of up to 38.1°C showing no improvement with oral antibiotics (levofloxacin), fatigue and a productive cough with mucous sputum. The pain was provoked by breathing and thoracic movement. He also complained of severe lumbar pain. The fever, characteristically, was unaccompanied by rigor at its onset and did not affect his clinical condition, which was good, apart from the thoracic and lumbar pain.

The past medical history included heavy smoking (100 packs/year, until 7 years previously). He reported ischaemic heart disease, with coronary angioplasty 6 years earlier, for which he was under medication, uncontrolled hypertension, atrial fibrillation with at least 2 episodes of paroxysmal tachycardia and shortness of breath during the previous 3 months, diabetes mellitus, controlled with oral medication, rheumatoid arthritis (RA) diagnosed 2

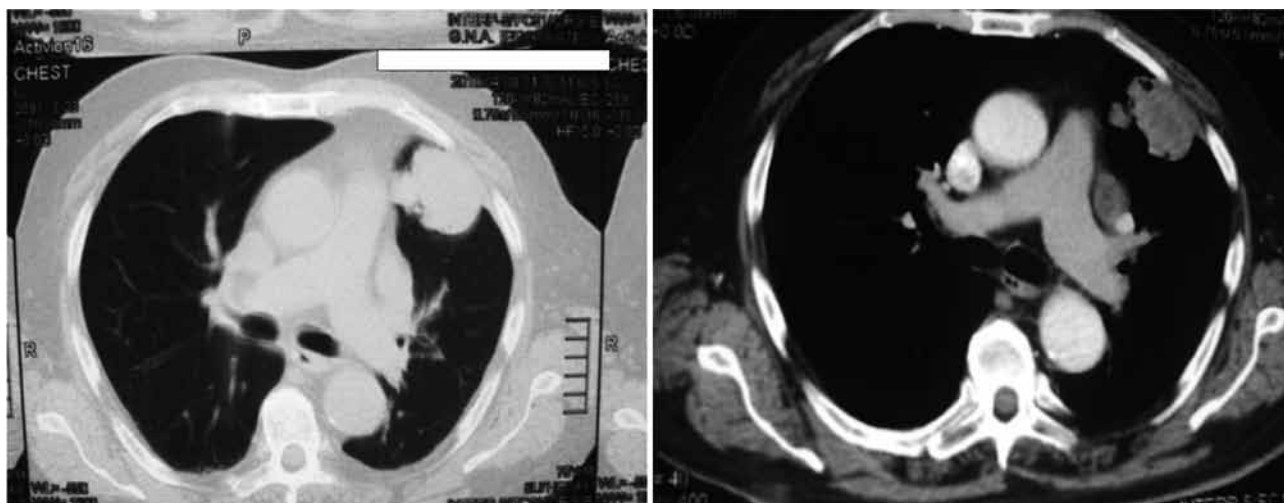
years earlier, treated with low dose corticosteroids (5mg prednisone daily), and prostate cancer treated by radical prostatectomy in 2001 with negative follow up. He had frequently consulted doctors for epigastric symptoms, due to a known diaphragmatocele.

On physical examination, auscultation of the lungs revealed diminished breath sounds over the left middle and lower lung fields, and pressure to the thoracic and lumbar spine elicited tenderness, but there were no other findings of note. Blood tests showed anaemia; haematocrit (hct) 33.1%, and haemoglobin (Hb) 10.4 g/dl, with the pattern of chronic disease. The serum chemistry finding that attracted attention was the raised level of lactic dehydrogenase (LDH), 600 IU/l (upper normal value of 190 IU/l), which showed gradual increase over the following days, up to 1015 IU/l.

Chest X-ray (figure 1) showed an opacity with a lobulated contour at the level of the left hilum, which did not obliterate the left border of the mediastinum. There was also widening of the ipsilateral hilum and mediastinum, together with a nonhomogeneous opacity of the left lower lung field and calcification in the left hemidiaphragm. Chest computed tomography (CT) (figure 2) showed a large (diameter ~5cm), round, solid tumour in the left upper lung lobe, with a lobulated contour and peripheral localization (adjacent to the pleura, which explains the patient's severe thoracic pain), with enlarged lymph nodes above the left main pulmonary artery (nodal station 5, according to ATS – aortopulmonary window), findings consistent with a malignant, space occupying lesion of the



**FIGURE 1.** Chest X-ray, showing an opacity with lobulated contour contiguous with the left hilum, widening of the ipsilateral hilum and mediastinum, nonhomogeneous opacity of the left lower lung field, and calcification of the left hemidiaphragm.



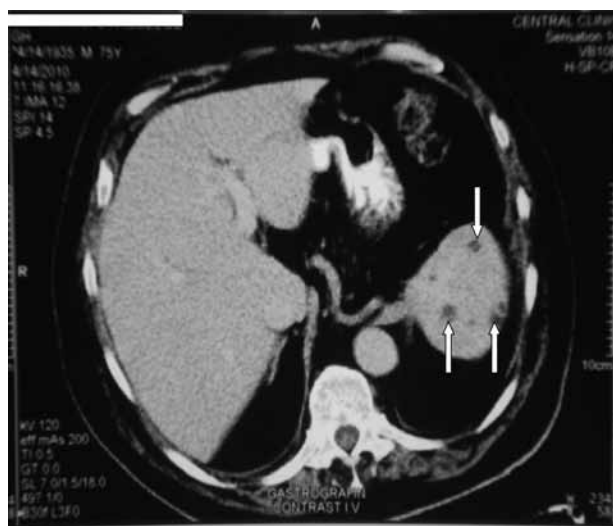
**FIGURE 2.** Chest CT showing a peripheral mass in the left upper lobe with enlarged lymph nodes at nodal station 5 (aortopulmonary window).

left lung, with ipsilateral mediastinal lymphadenopathy.

In view of the patients' febrile state investigation focused on the possibility of infection or exacerbation of RA. Gram staining and culture of sputum, blood and urine culture, investigation for tuberculosis (sputum and gastric lavage) and immunologic assay for a variety of infections were all negative. As indices of infective and immunological activity, such as erythrocyte sedimentation rate (ESR), serum C-reactive protein (CRP), procalcitonin, rheumatoid factor, anti-nuclear antibodies (ANA) and cyclic citryllinated peptide (CCP), were within the normal range, the possibility of an infectious or autoimmunological cause for the fever, was considered very remote.

The next step was the staging of the lesion with CT of the upper abdomen (figure 3), which showed multiple low density lesions in the spleen, compatible with metastases, CT of brain, which showed at least 3 higher density lesions, also concordant with metastases, confirmed by brain MRI. Because of the severe lumbar pain, MRI of thoracic and lumbar spine was performed, which showed multiple metastatic lesions in the thoracic and lumbar vertebrae. The staging thus showed that we were dealing with a tumour at a late stage, with multiple metastases, and consequently inoperable.

In an attempt to determine the exact histopathological nature of the lesion, bronchoscopy was precluded by the serious cardiological problems of the patient, and the peripheral localization of the tumour. Consequently trans-thoracic biopsy (FNB) with CT guidance was performed. The histology showed extensive infiltration of the lung



**FIGURE 3.** CT of the upper abdomen showing low density lesions in the spleen, compatible with metastases (white arrows).

parenchyma by malignant cells, with morphological and immunohistochemical characteristics consistent with the diagnosis of malignant melanoma. Specifically, the tumour contained middle and large sized cells, with significant mitotic activity and the presence of large amounts of dark cytoplasmic pigment (melanin). Staining with S-100 and HMB-45 were positive, while staining with chromogranin and cytokeratins were negative, findings compatible with malignant melanoma (figure 4).

The next important step in the diagnostic evaluation

of a malignant melanoma of the lung, is to clarify whether this is a primary lesion or is secondary to another, more common, primary site. Detailed skin and ophthalmological examination, and a thorough investigation of the GI tract (with gastroscopy and colonoscopy) produced negative results, and the extremely rare diagnosis of PMML was established. The persistent fever was attributed to the numerous spleen metastases.

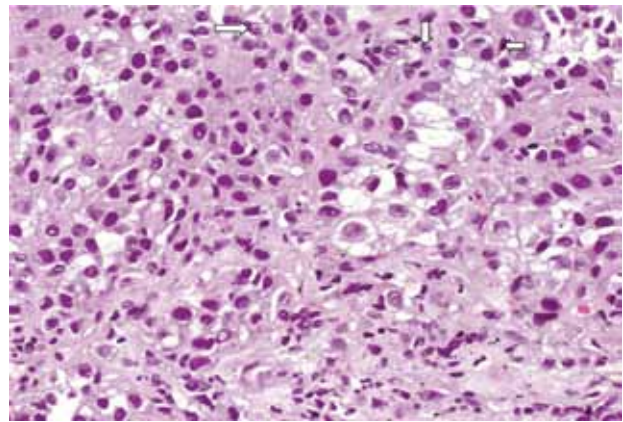
The patient was referred to the oncology department for chemotherapy and combined radiotherapy of the brain and bone metastases, but he eventually died 3 months after diagnosis.

## DISCUSSION

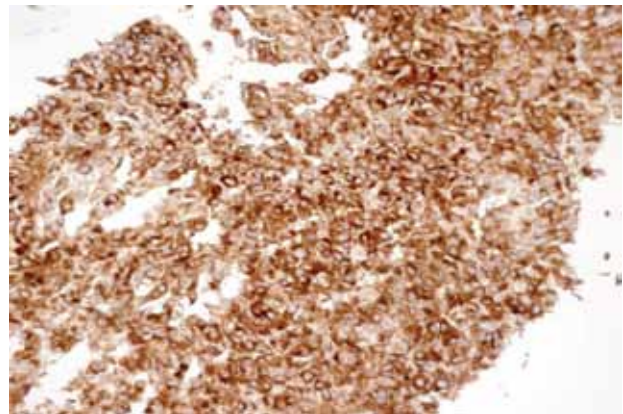
PMML represents an extremely rare sub-category of primary non-cutaneous melanomas, as only a few tens of cases have been reported in the world literature,<sup>1,2</sup> and it accounts for only 0.01% of all primary lung malignancies.<sup>1</sup> Apart from its rarity, the other reason that renders this entity worthy of report is the challenge that its diagnosis presents to the clinician, as clinically and radiologically, it does not differ from the more usual primary bronchogenic lung cancer,<sup>1,3</sup> while its histology and immunohistochemistry cannot discriminate it from a lung metastasis from other forms of primary melanoma, which are more common. In addition, this case of PMML presented with splenic metastases, which is an unusual localization for malignant melanomas, and manifested clinically as persistent fever.

PMML usually appears as a solitary, central endobronchial neoplasm, although in this case it had a peripheral distribution. In 30% of all cases, it may be a symptomless incidental finding on routine chest X-ray, but due to its usual central, endobronchial localization, it may present with cough, haemoptysis, post-obstructive pneumonia or atelectasis.<sup>1,3,19</sup> Regarding its epidemiology, there is no statistically significant difference of PMML incidence between men and women, and the mean age at diagnosis is 51 years (reported range 45-71 years).<sup>2</sup>

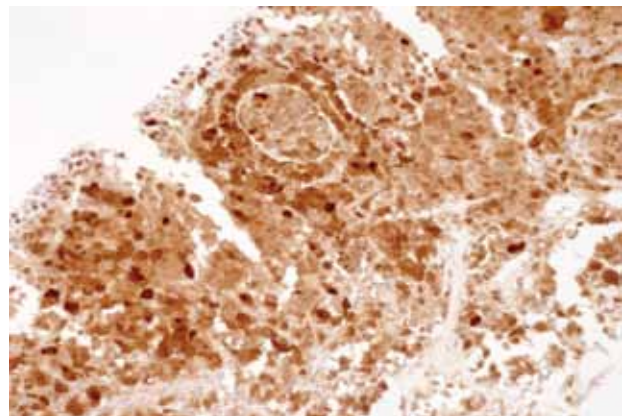
The histological characteristics of this tumour are the same as of the other primary melanomas, so they cannot distinguish PMML. The predominant findings are large epithelioid cells (figure 4a), loosely cohesive, with large, round hyperchromatic nuclei and prominent eosinophilic nucleoli.<sup>1,2</sup> A dark brown pigment (melanin) is observed in the cytoplasm of the neoplastic cells. Immunohistochemical staining offers little help in discrimination between PMML and the other primary melanomas, as the results



**FIGURE 4A.** (H-E staining, original magnification  $\times 40$ ). Histology slides of lung biopsy compatible with malignant melanoma. Cellularly rich neoplasm, consisting mainly of large cells, pleomorphic, with prominent nucleolar atypia, and cytoplasmic inclusions of melanin (white arrows).



**FIGURE 4B.** The same sample (magnification X40) with immunohistochemical staining for HMB-45(+).



**FIGURE 4C.** The same sample (magnification X40) with immunohistochemical staining for S-100(+).

have low specificity. S-100, HMB-45 stains and vimentin appear to have a diffuse strong positivity in PMML (figures 4b, 4c), whereas cytokeratin, CAM 5.2, and chromogranin are usually negative, but these results can also be found in primary melanomas in other sites.<sup>1,2</sup>

The differential diagnosis of PMML includes non-small cell lung cancer, especially the large cell subtype, melanocytic carcinoid tumour, melanotic paraganglioma or schwannoma and, of course, pulmonary metastases from primary melanomas of other sites, which are more usual (skin, head and neck mucosae, eye, GI tract, female reproductive system). The final diagnosis of PMML is established, based on a combination of clinical, radiological and histopathological findings, according to the following criteria:<sup>1,2</sup>

- A) junctional changes of the bronchial epithelium, with invasion of intact bronchial mucosa by malignant melanoma cells
- B) histological and immunohistochemical confirmation that the above changes arise from malignant melanoma cells
- C) the radiological appearance of a solitary lung tumour
- D) no previous history or present clinical or laboratory findings of a cutaneous, mucosal or ocular melanoma.

The case presented above fulfils these diagnostic criteria.

Regarding the pathogenesis of PMML, there are several theories.<sup>1,2</sup> One theory maintains that melanocytes pre-exist in the bronchial mucosa, as they have migrated there, as they migrate to other parts of the body, during embryogenesis. A second theory is that malignant melanocytes in the bronchial epithelium derive from a pluripotent stem cell, while a third theory speculates that these cells may arise from areas of squamous metaplasia of the normal bronchial epithelium, where some epithelial cells have undergone differentiation into melanocytes. This may account for the increased incidence of PMML in heavy smokers, as the above patient, who often show bronchial squamous metaplasia.<sup>1</sup>

The treatment of choice for PMML is an aggressive surgical approach, with lobectomy or pneumonectomy, whenever this is possible, as in patients with an early diagnosis and disease limited to one lung, and mediastinal lymph node involvement at the time of the operation does not preclude long time survival.<sup>1,2</sup> The main effort is to maintain as clear surgical margins as possible, in order to avoid recurrences. Of 32 cases of PMML that have been reported, 5 cases were not operated on, as 2 were diagnosed at autopsy, while the other 3 tumours were

unresectable, and the patients died within 4 months of diagnosis. Of the 27 patients that were operated on, only 8 remained free of disease, and these were the ones that underwent lobectomy or pneumonectomy. The disease free survival duration ranged from 6 months to 11 years.<sup>3,9-12</sup> As a conclusion, the prognosis for unresectable cases of PMML is very bad, being only a few months, as these patients have disseminated disease. The prognosis better for patients with limited disease, who have undergone radical surgical intervention.

Because of the aggressive biological behaviour of the tumour, surgery alone may be insufficient. Post-operative adjuvant chemotherapy is proposed, with agents such as dacarbazine, IL-2, IFN.<sup>13</sup> The same regimens have been used for treatment of unresectable metastatic melanoma.<sup>14</sup> Most data have been documented for skin melanoma, for which these measures occasionally show dramatic success, especially as adjuvant chemotherapy for limited resectable disease, but the overall success rate for metastatic melanoma is quite low.<sup>15</sup> Experience with PMML is very limited because of its rarity, but the treatment regimes that have been proposed are similar to those for melanomas arising from the skin.<sup>16</sup> Radiation therapy can be used post-operatively for patients with locally advanced melanoma, in an attempt to reduce the rate of local recurrence, but it does not prolong survival. It can also be used for patients with unresectable distant metastases (brain, bones), as palliation treatment.<sup>17</sup>

Metastases to the spleen are considered a rare event for any form of malignant melanoma, and when they occur they are a sign of end-stage, widespread disease, and are traditionally treated with systemic chemotherapy regimes.<sup>20,21</sup> It has been reported that for a solitary spleen metastasis, with no evidence of disease elsewhere, splenectomy can be considered as a therapeutic option.<sup>21</sup> The numerous spleen metastases of the patient presented here were considered to be the cause of his persistent fever, as the spleen is an immune organ, with extensive lymphoid tissue and fever in this case can be regarded as a paraneoplastic immunological manifestation.<sup>18</sup>

## REFERENCES

1. Dountsis A, Zisis C, Karagianni E, Dahabreh J. Primary Malignant Melanoma of the Lung: A case report. *World Journal of Surgical Oncology* 2003;1:26
2. Pan Xu-dong, Zhang Bin, Guo Ling-chuan, Gu Dong-mei et al. Primary Malignant Melanoma of the lung in the elderly: case report and literature review. *Chinese Medical Journal* 2010;123:1815-1817

3. Wilson RW, Moran CA. Primary melanoma of the lung: a clinicopathologic and immunohistochemical study of eight cases. *Am J Surg Pathol* 1997;21:1196-202.
4. Winston W. Tan: Malignant melanoma. e-medicine oncology, [www.e-medicine.medscape.com](http://www.e-medicine.medscape.com), Date updated: June 1, 2010.
5. Kim Kevin. Non – Skin Melanomas. Cancer blog from MD Anderson Cancer Center, [www.mdanderson.org](http://www.mdanderson.org), Date accessed: June 3, 2009.
6. McLaughlin CC, Wu XC, Jemal A et al. Incidence of noncutaneous melanomas in the US, *Cancer* 2005;103:1000.
7. Chang AE, Karnell LH, Menck HR. The National Cancer Data Base report on cutaneous and noncutaneous melanoma: a summary of 84,836 cases from the past decade. The American College of Surgeons Commission on Cancer and the American Cancer Society. *Cancer* 1998;83:1664.
8. Wong JH, Cagle LA, Storm FK, Morton DL. Natural history of surgically treated mucosal melanoma. *Am J Surg* 1987;154:54
9. Ulger AF, Sen E, Ereku S, Gonullu U. Malignant melanoma of the lung: is it easy to determine its origin? *Arch Bronconeumol* 2005;41:102-104.
10. Kundranda MN, Clark CT, Chaundry AA et al. Primary malignant melanoma of the lung: a case report and review of the literature. *Clin. Lung Cancer* 2006;7:279-281.
11. Reddy VS, Mykytenko J, Giltmann LI et al. Primary malignant melanoma of the lung: review of literature and report of a case. *Am Surg* 2007;73:287-289.
12. Maeda R, Isowa N, Onuma H et al. Primary malignant melanoma of the lung with rapid progression. *Gen Thorac Cardiovasc Surg* 2009;57:671-674.
13. Kirkwood JM, Strawderman MH, Ernstoff MS et al. Interferon a-2b adjuvant therapy of high risk resected cutaneous melanoma: The Eastern Cooperative Oncology Group trial EST 1684. *J Clin Oncol* 1996;14:7.
14. Atkins MB. The role of cytotoxic chemotherapeutic agents either alone or in combination with biological response modifiers. In: *Molecular Diagnosis, Prevention and Therapy of Melanoma*. Kirkwood JK (Ed), Marcel Dekker, New York 1997. p.219.
15. Bajetta E, Del Vecchio M, Bernard-Marty C et al. Metastatic melanoma: chemotherapy. *Semin Oncol* 2002;29:427-445.
16. Kim KB, Sanguino AM, Hodges C et al. Biochemotherapy in patients with metastatic anorectal mucosal melanoma. *Cancer* 2004;100:1478.
17. Bastiaannet E, Beukema JC, Hoekstra HJ. Radiation therapy following lymph node dissection in melanoma patients: treatment, outcome and complications. *Cancer Treat Rev* 2005;31:18-26.
18. Tang H, Huang H, Xiu Q, Shi Z. Isolated splenic metastasis from lung cancer: ringleader of continuous fever. *Eur Respir Rev* 2010;19:117,253-256.
19. Ost D, Joseph C, Sogoloff H, Menezes G. Primary Malignant melanoma: case report and literature review. *Mayo Clin Proc* 1999;74:62-6.
20. Klein B, Stein M, Kuten A, et al. Splenomegaly and solitary spleen metastasis in solid tumors. *Cancer* 1987;60:100-2.
21. Trindade MR, Blaya R, Trindade EN. Melanoma metastasis to the spleen: Laparoscopic approach. *J Minim Access Surg* 2009;5:17-19.